



A hip surveillance program for children with cerebral palsy can effectively identify silent hip displacement, or “hip dysplasia.” If untreated, hip displacement may cause pain or loss of function in the future.

A Hip Surveillance assessment includes:

- Obtaining a standardized x-ray for hip surveillance and measuring each hip’s Migration Percentage
- Assessing the child’s Gross Motor Function Classification System (GMFCS)
- Examining the child’s hip range of motion



Standardized X-Rays for Hip Surveillance

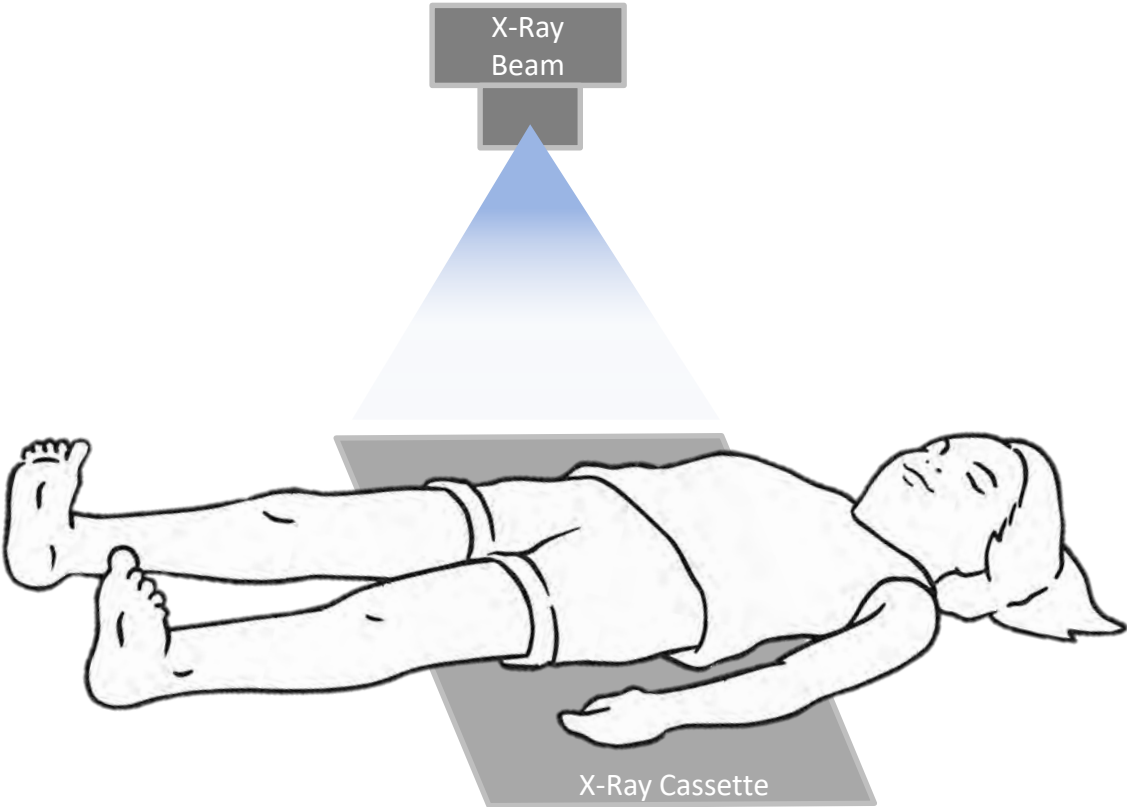
A standardized x-ray is critical for evaluation of silent hip displacement in children with cerebral palsy. Without treatment, silent hip displacement is progressive and can lead to pain and loss of function in the future.

The best x-ray for evaluation of the hips in a hip surveillance program is an

“Anterior-Posterior (AP) Pelvis X-Ray.”

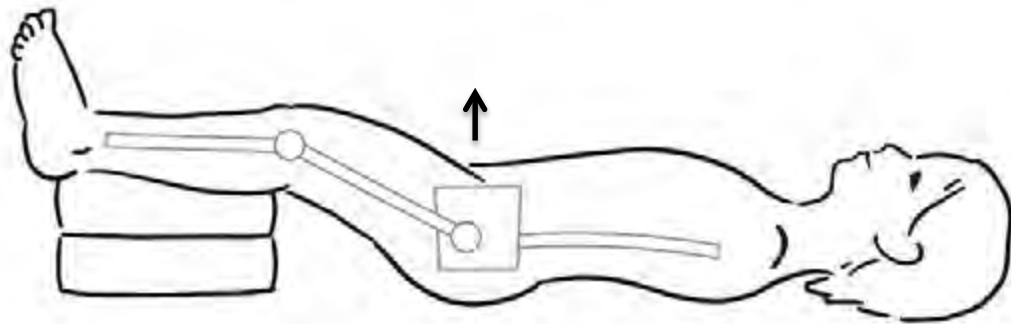
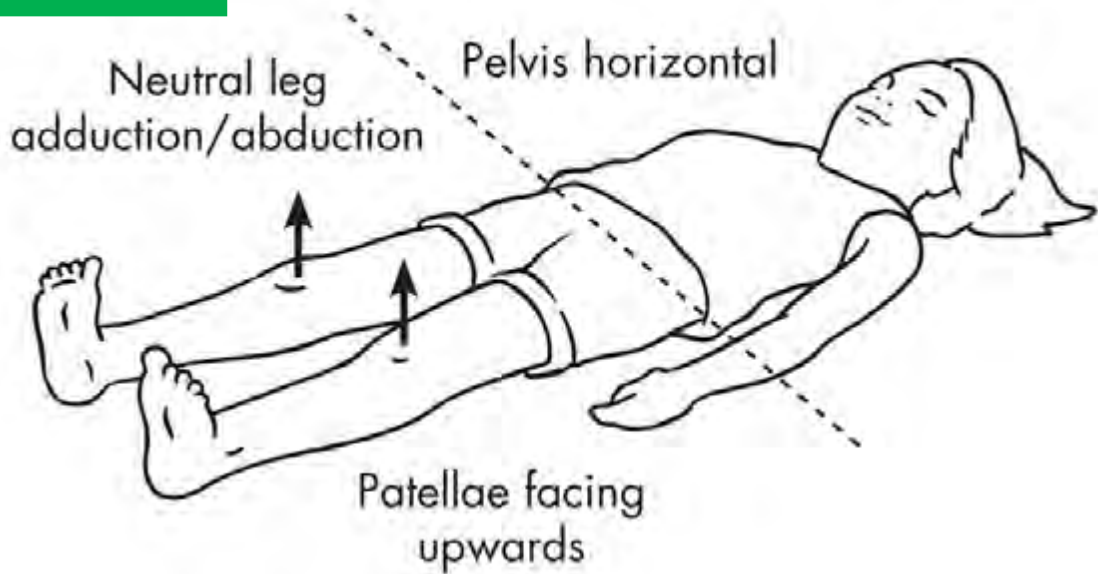
This x-ray will show both hips and the entire pelvis, giving the greatest information with a very low dose of radiation (60 millirems). Click [here](#) for more information on radiation exposure.

The child is positioned on an x-ray table, and the x-ray cassette is placed under the child. The x-ray beam is directed from anterior (front) to posterior (back).

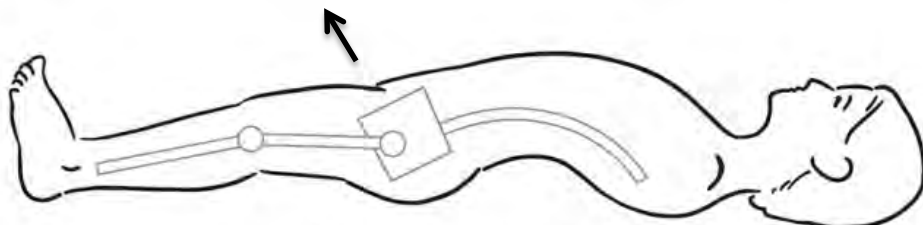


Proper positioning of the child during the x-ray is critical for accuracy of the assessment. Children should be positioned as follows:

- Pelvis horizontal
- Legs in neutral position. The legs should not be spread apart (“abduction”) or crossed (“adduction”).
- Knee caps (or “patellae”) pointing forward. The feet may not necessarily point upwards.
- Some children cannot completely straighten their hips because of stiffness, called a “hip flexion contracture.” If a hip flexion contracture is present, the lower legs should be positioned on pillows to prevent tilt of the pelvis.



If a hip flexion contracture is present, use pillows to keep the pelvis facing forward



Without the pillows, the hip flexion contracture tilts the pelvis

The Radiology Protocol for Hip Surveillance tab contains a PDF that can be given to any X-Ray Department to help ensure a properly positioned AP Pelvis X-Ray.



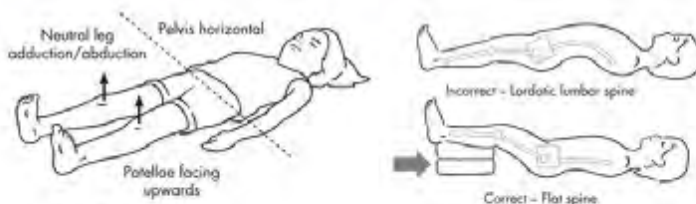
Radiology Protocol for Cerebral Palsy Hip Surveillance AP Pelvis X-Ray

Study Requested: Supine Anterior-Posterior Pelvis X-Ray

Positioning details:

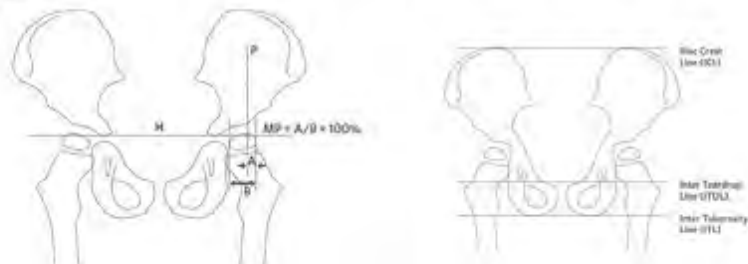
Children should be positioned as follows:

- Pelvis horizontal
- Hips and legs in neutral adduction/abduction
- Patella pointing forward (feet may not necessarily point up)
- If a hip flexion contracture is present, position the lower legs on pillows to prevent anterior pelvic tilt and lumbar lordosis



Reason For Request:

Please report the Migration Percentage (MP) for **each hip**, defined as the **percent of ossified femoral head that is not covered by the ossified acetabular roof**. In the left-sided figure below, **Migration Percentage = $A / B \times 100\%$**

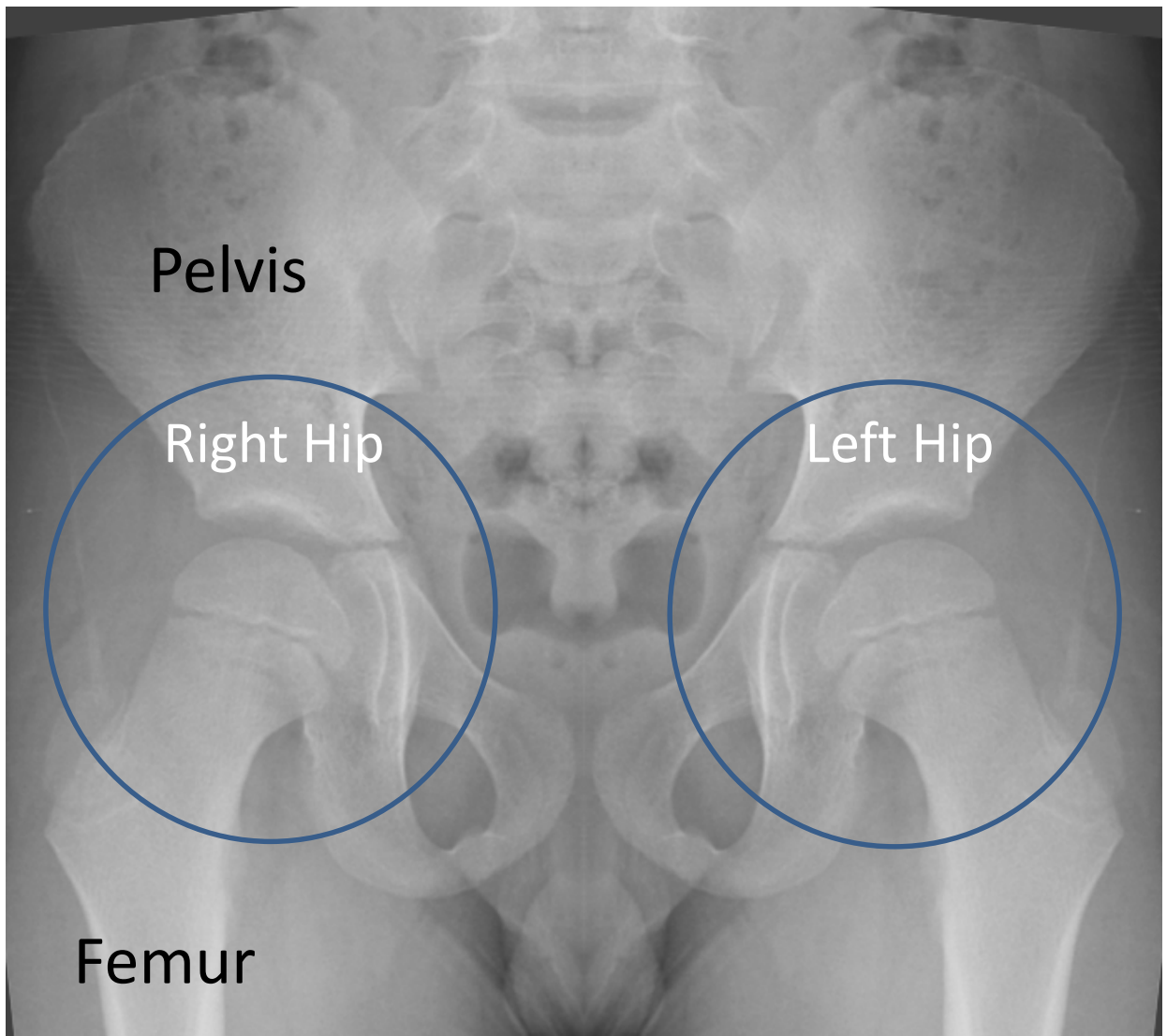


"H" line – Hilgenreiner's horizontal line connecting open tri-radiate cartilage

- if tri-radiate cartilage is closed, horizontal may be established by the alternative lines shown in the right-sided image, the Iliac Crest Line, Inter Teardrop Line, or Inter Tuberosity Line

"P" line – Perkin's perpendicular line at lateral edge of ossified acetabulum

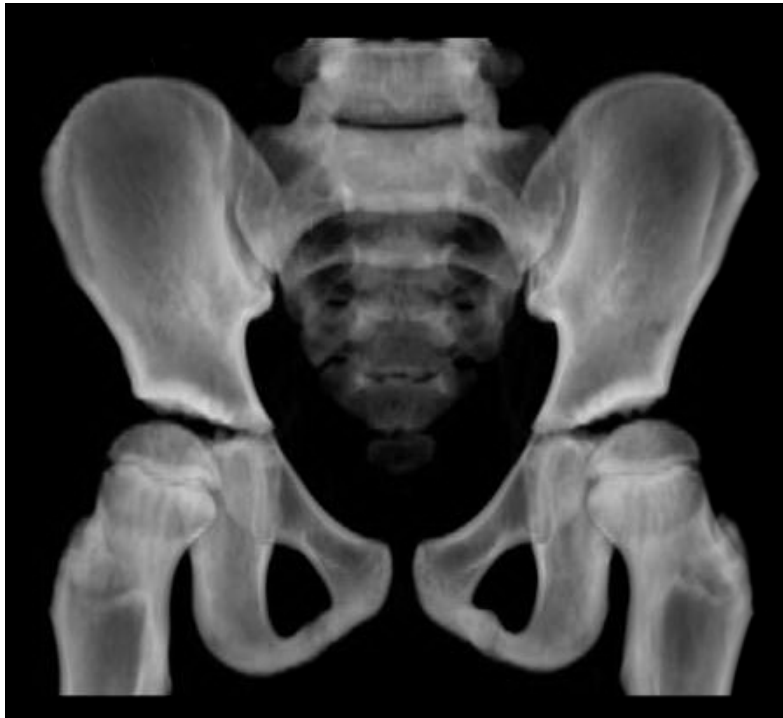A properly positioned AP Pelvis X-ray will show the following:



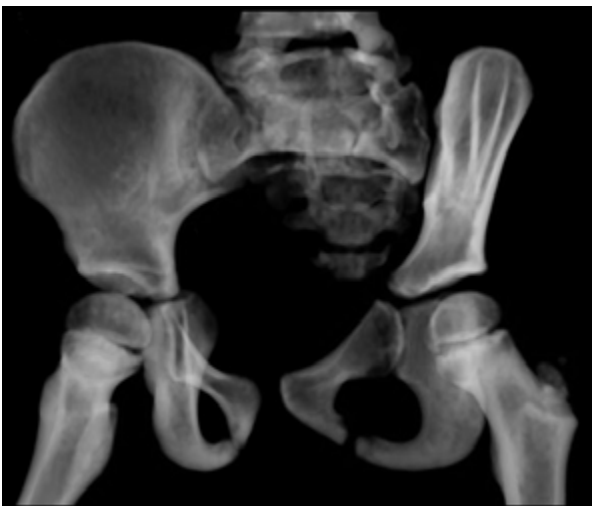The hip joints are circled. All AP Pelvis X-Rays are displayed *as if we are looking at the patient*. The patient's right hip and the patient's left hip are labeled using this convention.

A properly positioned AP Pelvis X-Ray (**A**) allows accurate assessment. When the pelvis is rotated (**B**) or tilted (**C**), the assessment may be inaccurate.

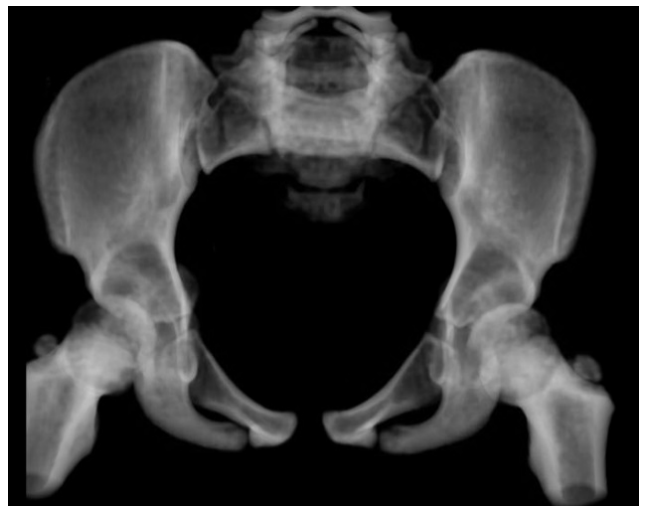A



B

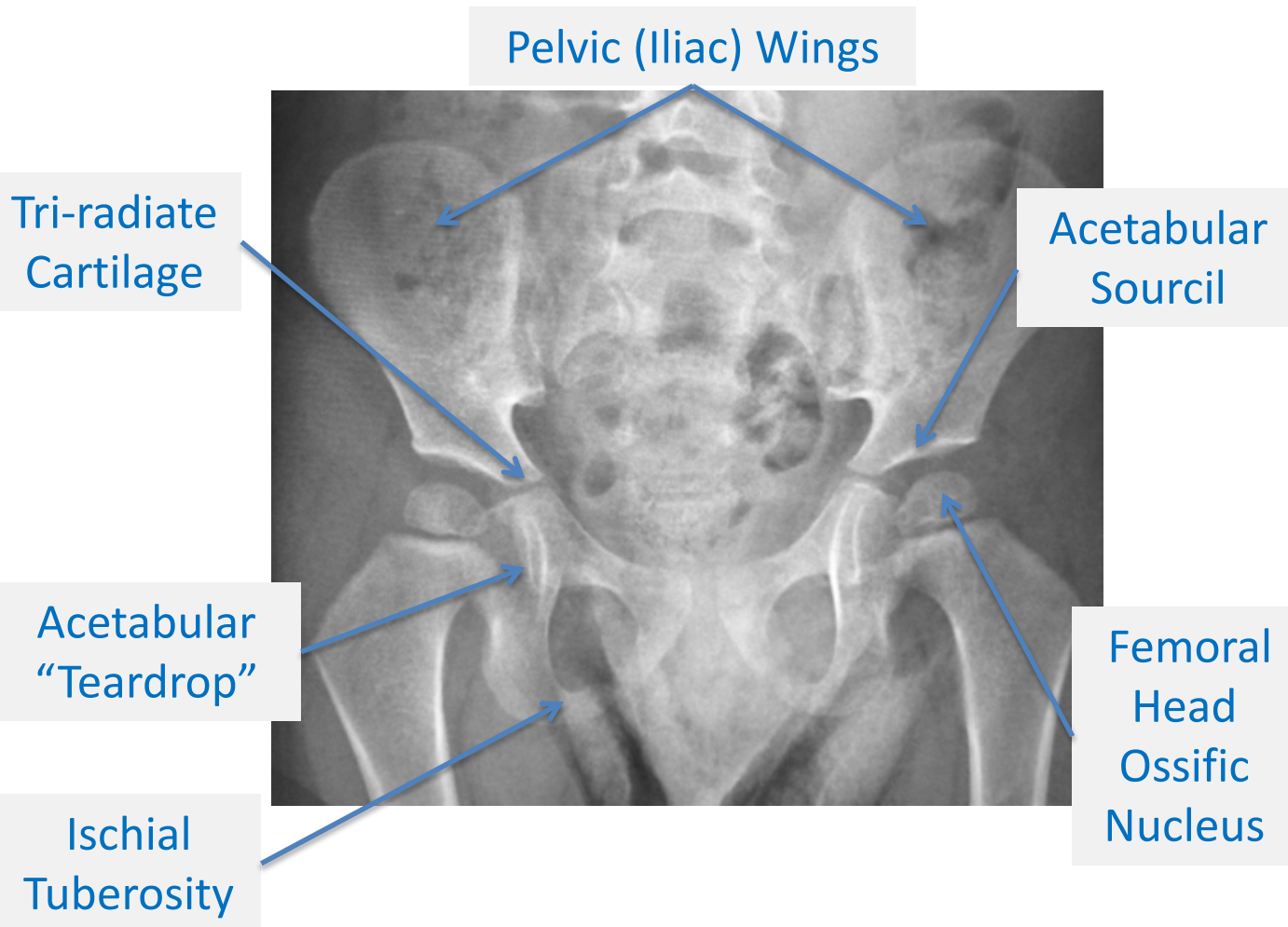


C



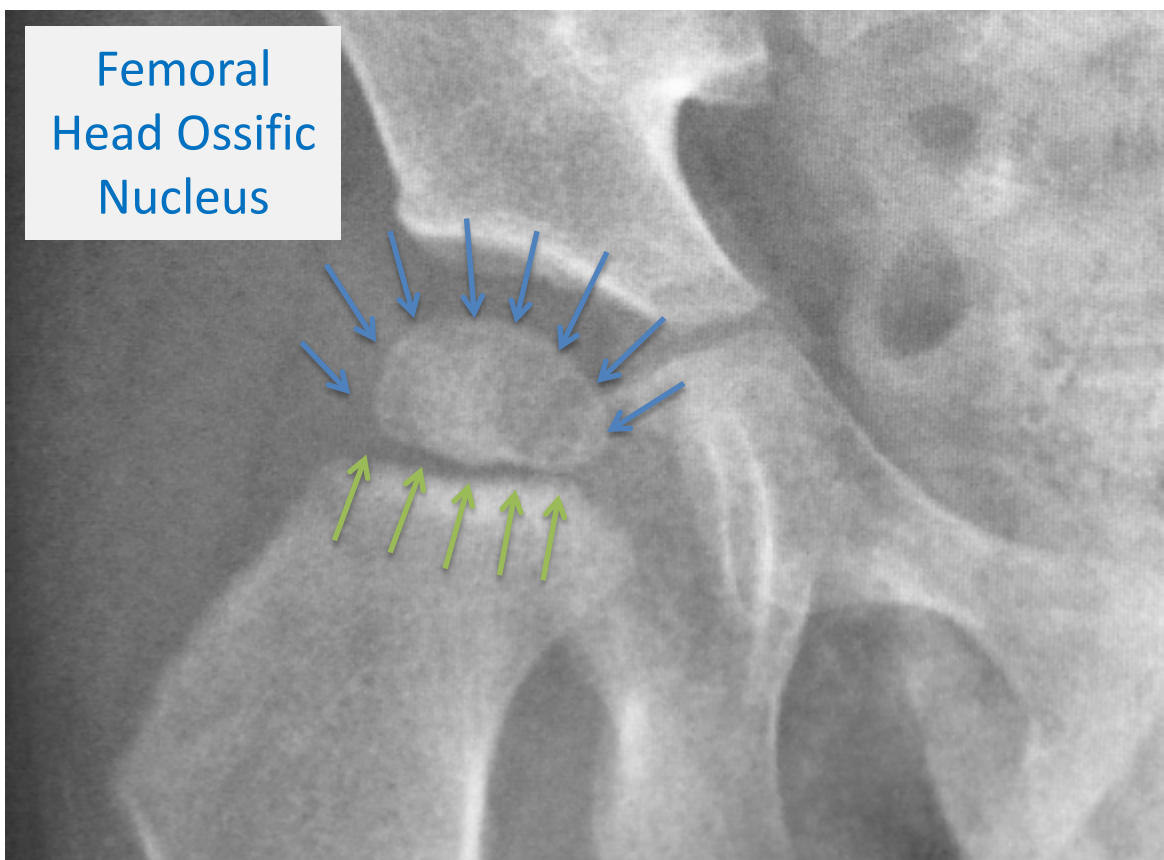


An anterior-posterior (AP) Pelvis X-Ray gives valuable information about the presence of hip dysplasia in a child with cerebral palsy. An AP Pelvis X-Ray has the following important landmarks:



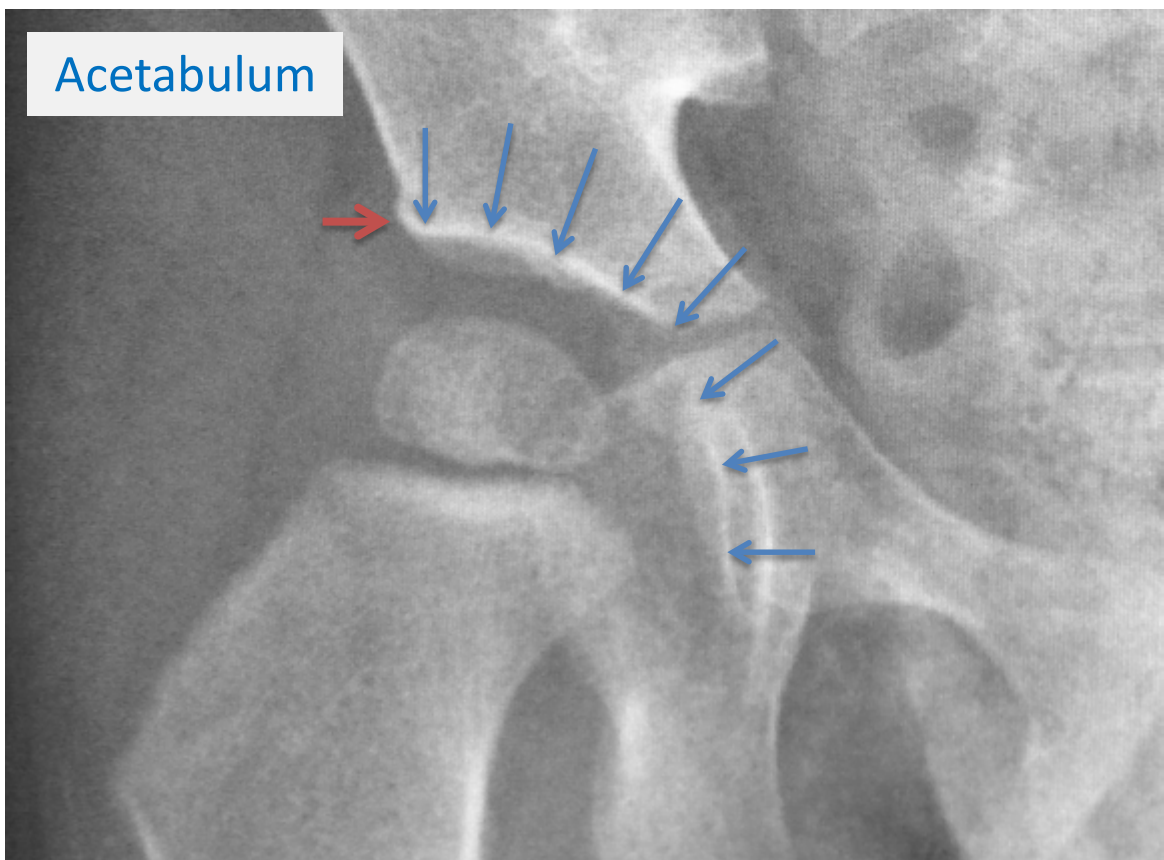
Femoral Head Ossific Nucleus:

The femoral head is the “ball” of the hip joint. The femoral head ossific nucleus is the white oval of bone outlined by arrows. The blue arrows show the upper edge of the ossific nucleus, and the green arrows show the growth plate of the femur bone (seen as a thin dark gray line). Bone appears white on x-ray, and the dark spaces between bones is cartilage.



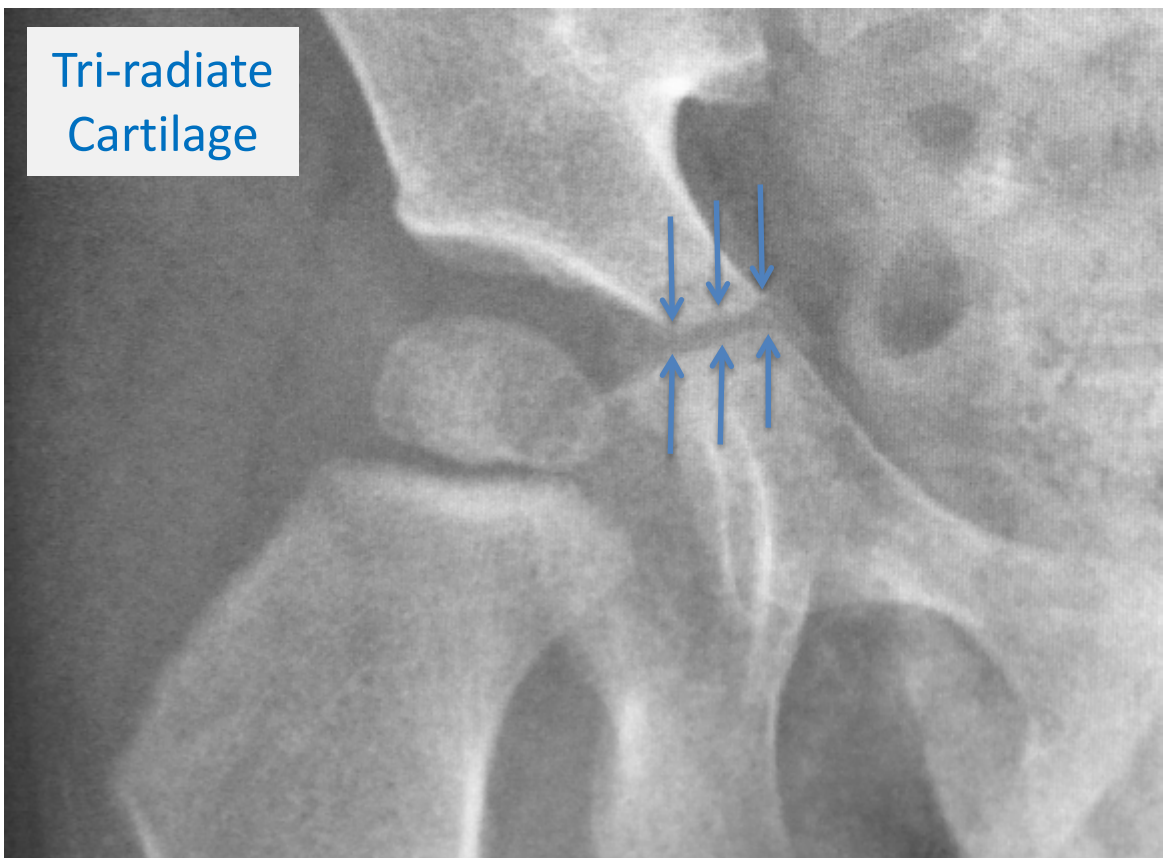
Acetabulum:

The acetabulum, or “hip socket,” is outlined by blue arrows. The shape of the acetabulum on x-ray can change over time. A round acetabulum and a round femoral head creates the best scenario for long-term hip health. The red line touches the edge of the acetabulum, an important landmark for hip x-ray assessments.



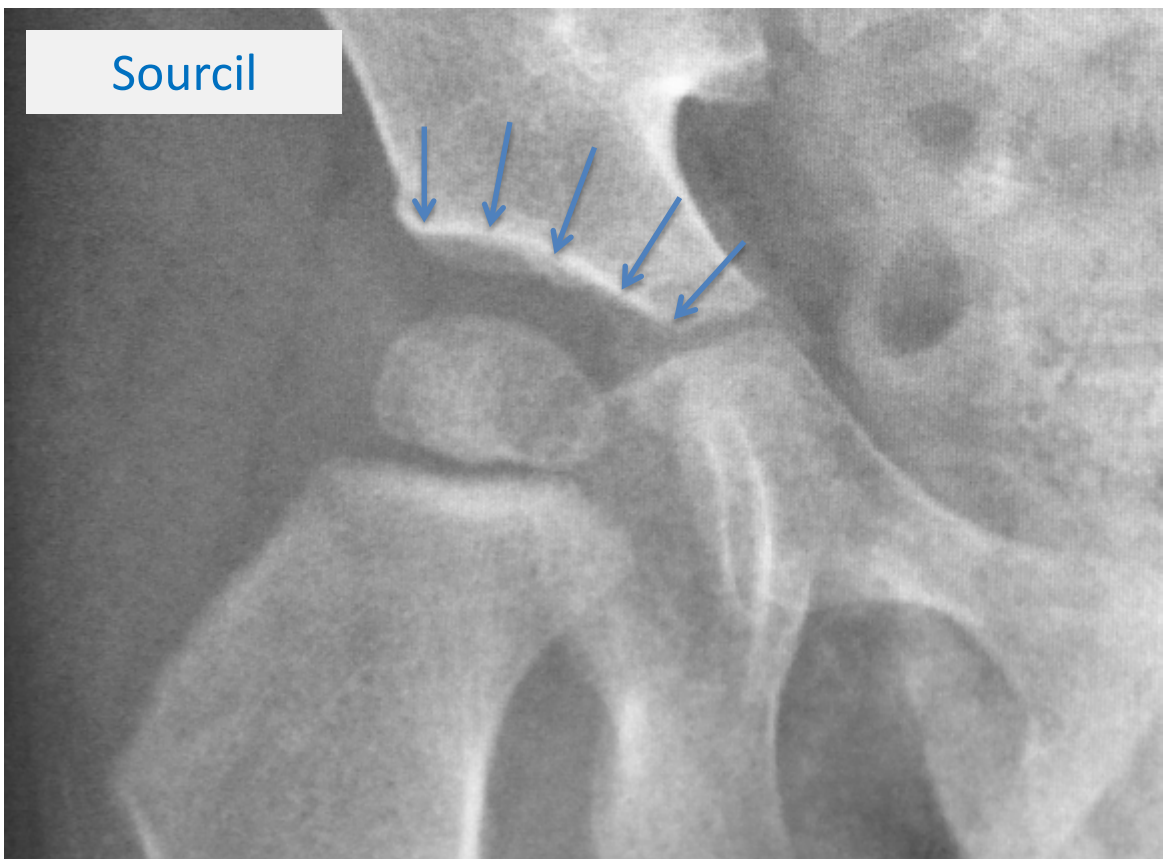
Tri-radiate cartilage:

The tri-radiate cartilage is a dark line on the x-ray between the bones of the pelvis, noted by the arrows. It is the growth plate of the acetabulum (hip socket). At skeletal maturity, the tri-radiate cartilage fuses into bone.



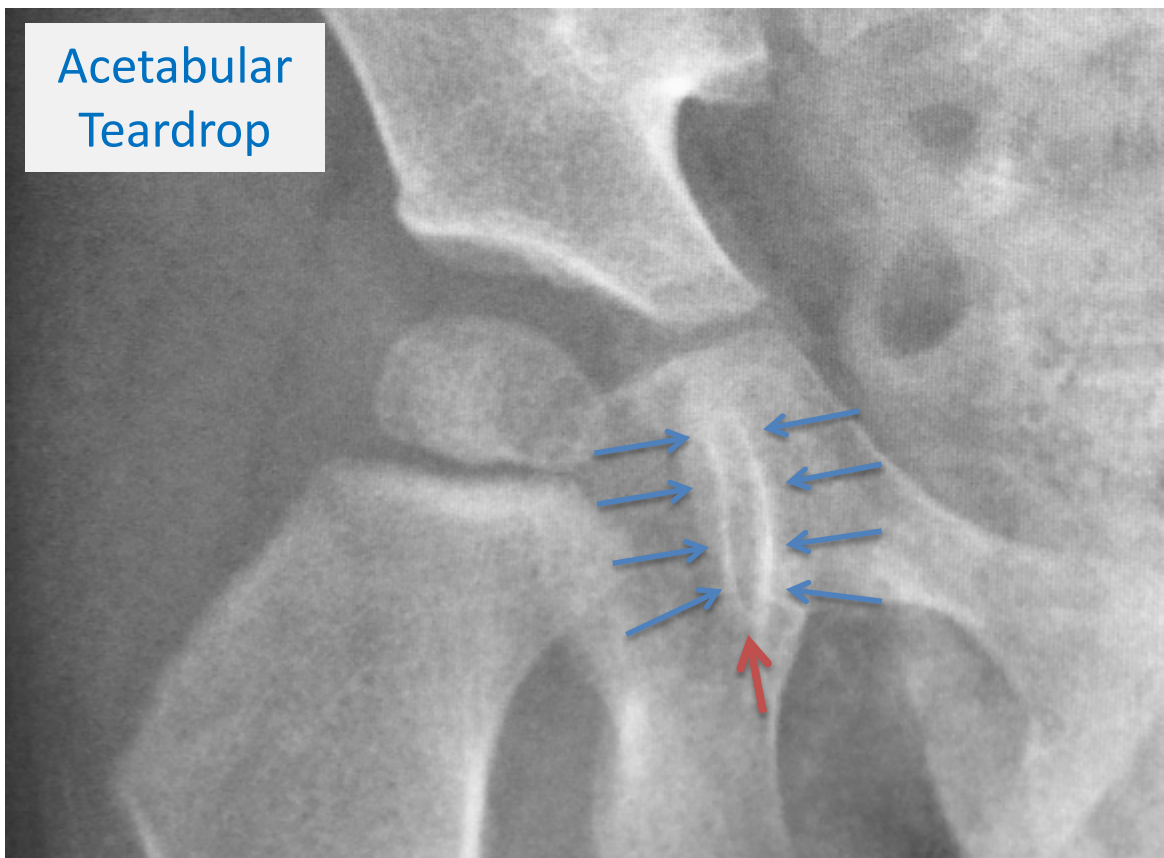
Acetabular Sourcil (or just “Sourcil”):

The sourcil is a line of dense (white) bone of the upper portion of the acetabulum. In the example below, it extends to the edge from the tri-radiate cartilage to the lateral edge of the acetabulum.



Acetabular Teardrop:

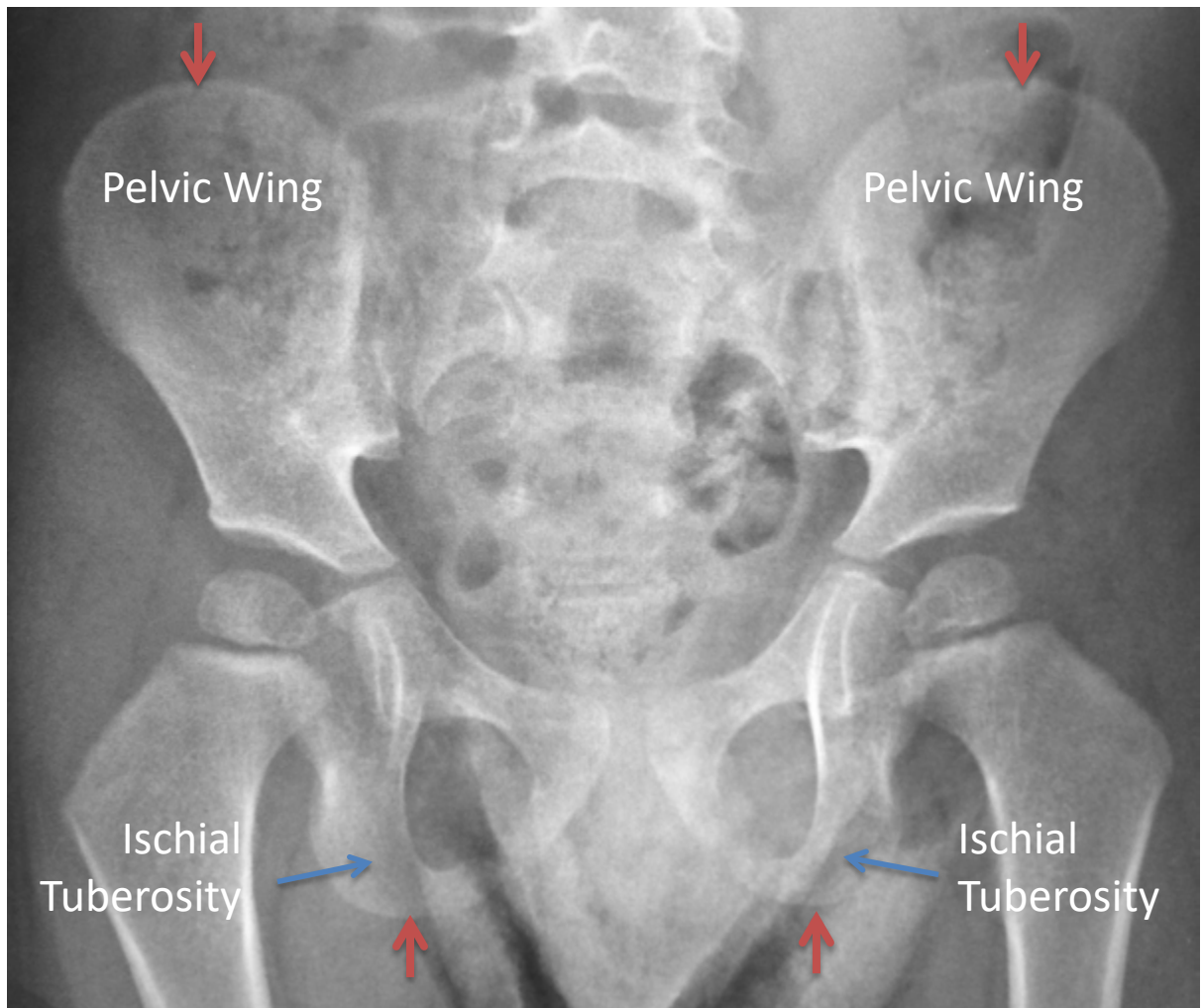The “teardrop” refers to a white U-shaped density of bone that marks the inner margin of the acetabulum. The bottom portion of the teardrop (marked with a red arrow) is an important landmark for hip measurements.



Pelvis:

The pelvis has two landmarks are important for hip measurements – the **pelvic wings** and the **ischial tuberosities**.

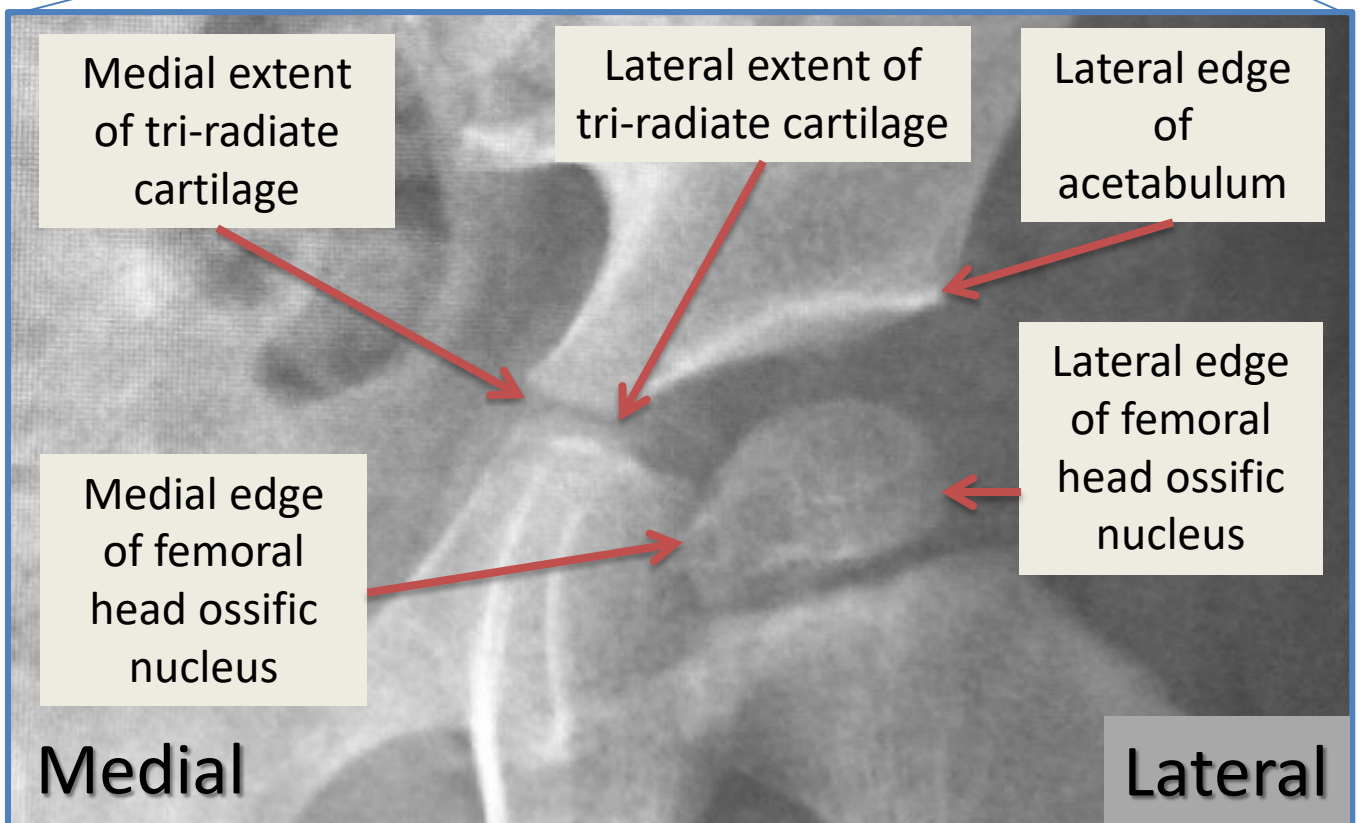
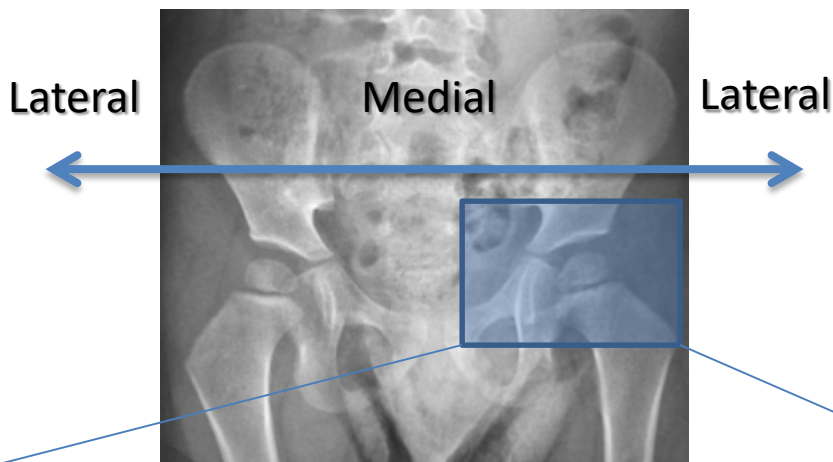
The red arrows show the upper-most margin of the pelvic wing and lower-most margin of the ischial tuberosity.




Definitions of Direction on the Pelvis:

The term “medial” refers to the part that is closer to the middle of the body.

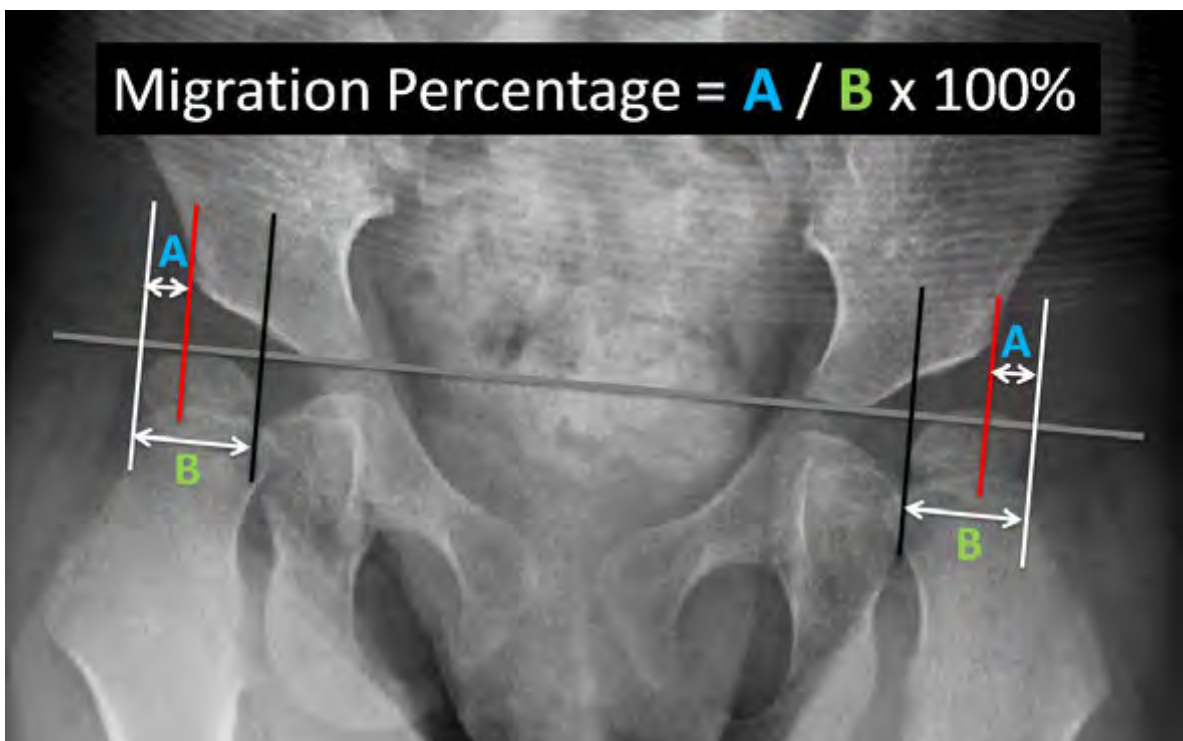
The term “lateral” refers to the part that is closer to either side of the body.





Measuring the Migration Percentage

The most important measurement on an x-ray obtained for hip surveillance is each hip's **migration percentage**, or the percentage of the femoral head ("ball") that is outside of the acetabulum ("socket").



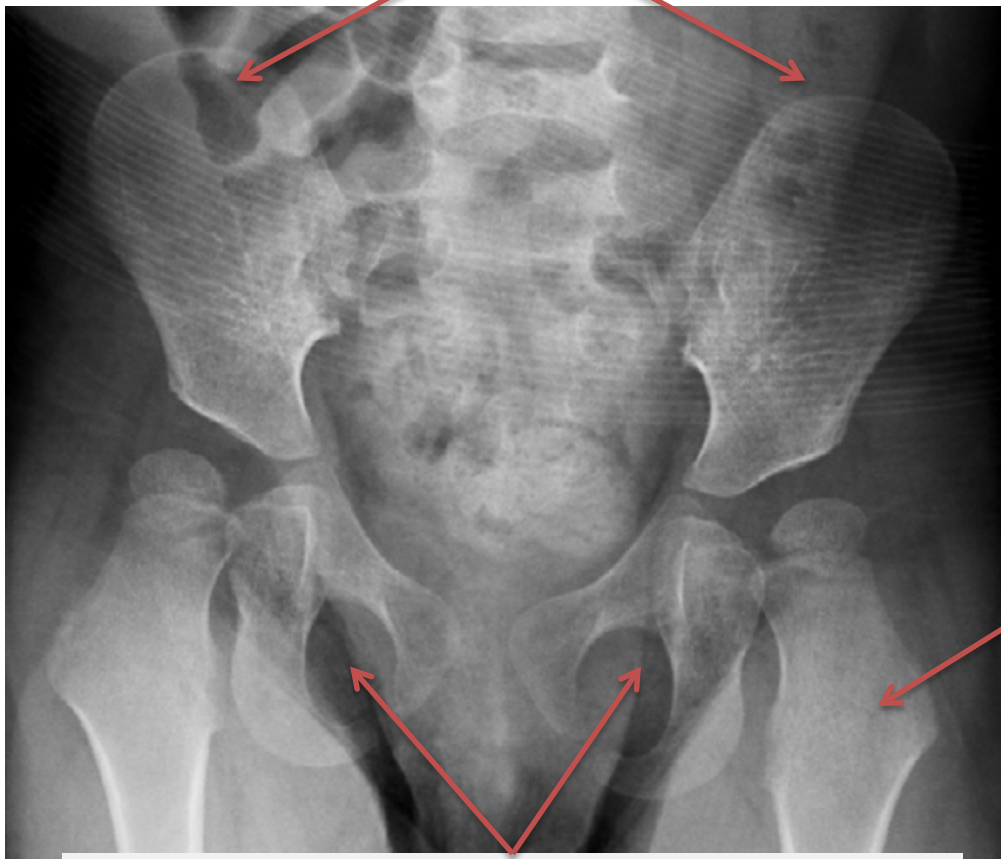
There is an increased risk of progressive hip displacement if the **migration percentage** is equal or greater than **30%**.

The Migration Percentage can be calculated in 4 steps.

STEP 1: Confirm that you have a properly positioned AP Pelvis X-ray.

A properly positioned AP Pelvis X-ray will have the following features:

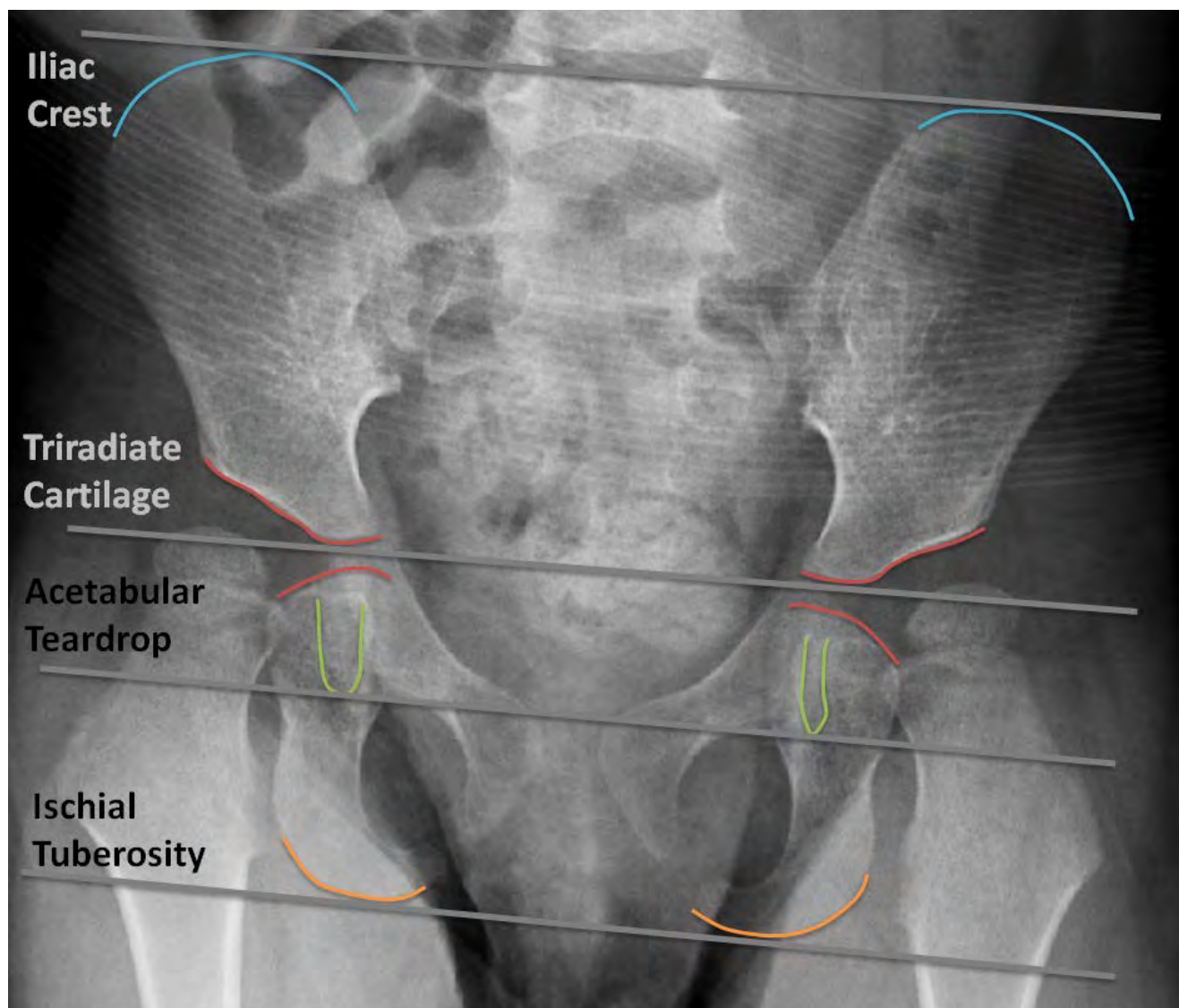
Symmetric pelvic wings



Hip & Femur in neutral abduction/adduction

Symmetric and oval obturator foramina

STEP 2: Establish the pelvis horizontal axis, or **H-line**, by connecting one of the pair of landmarks outlined below. The most common landmark to use is the Tri-Radiate Cartilage.

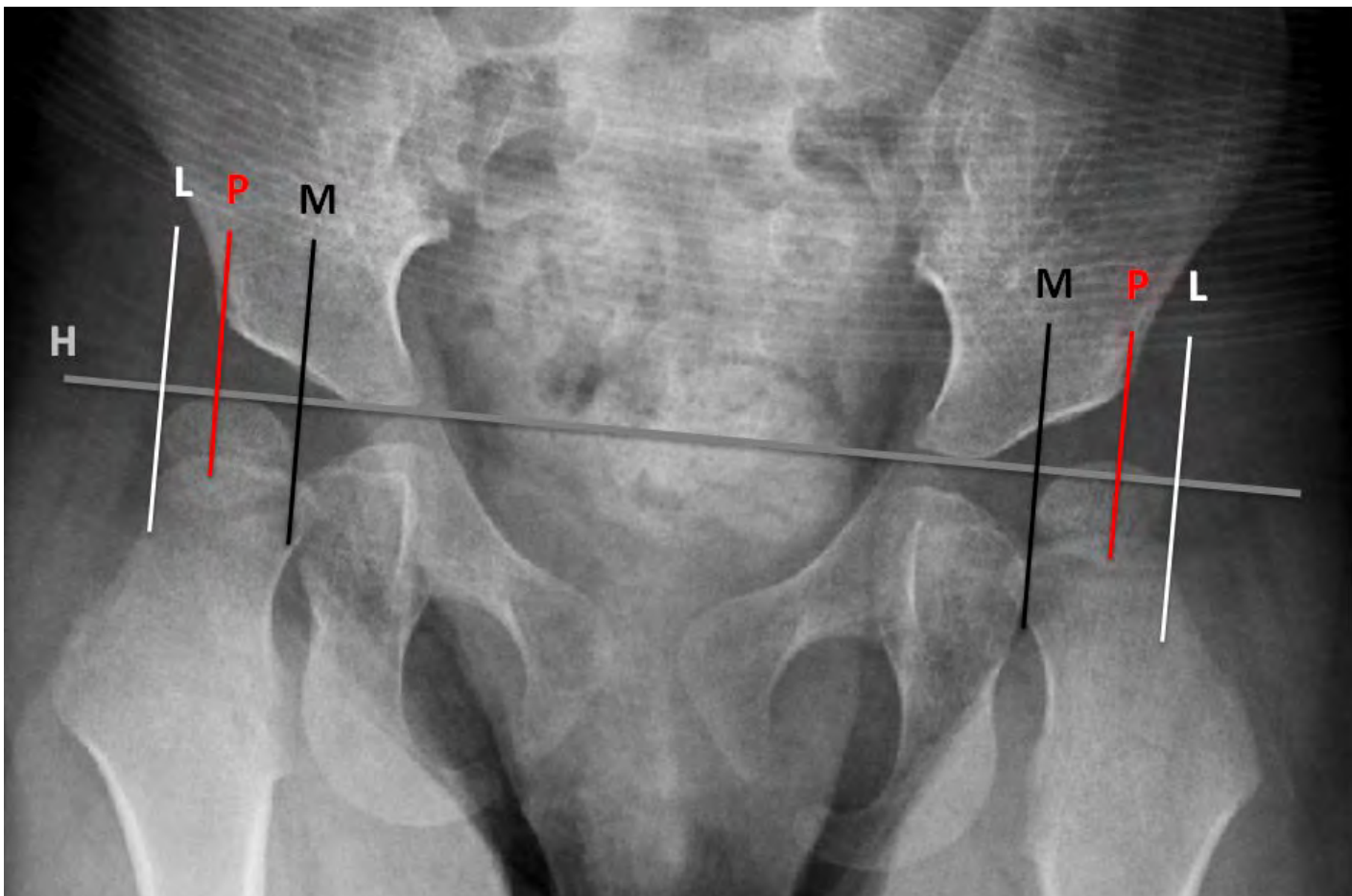


STEP 3: Draw three perpendicular lines to the H-Line:

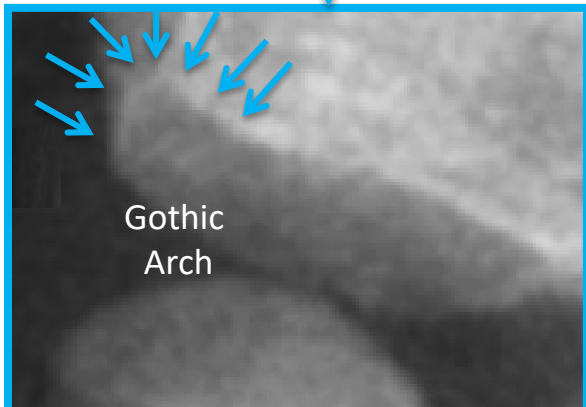
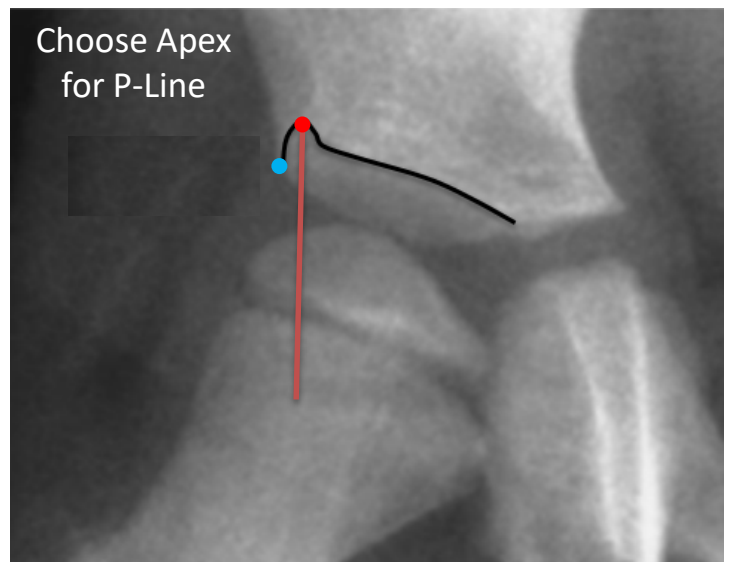
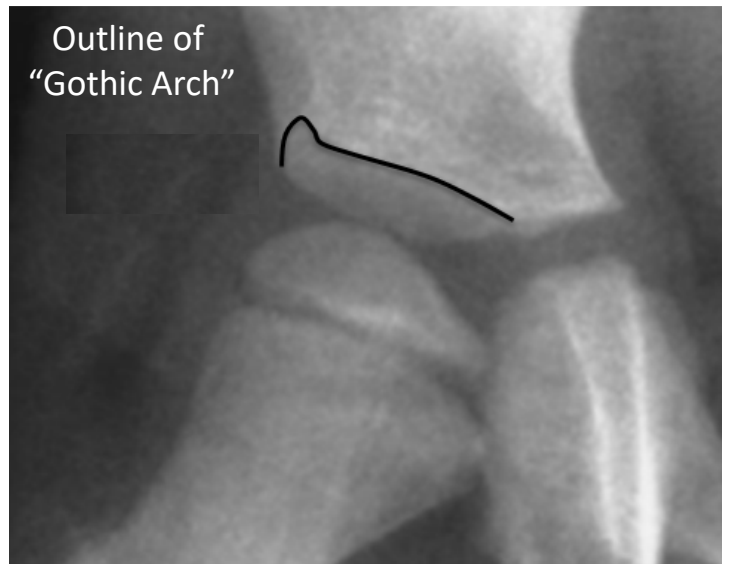
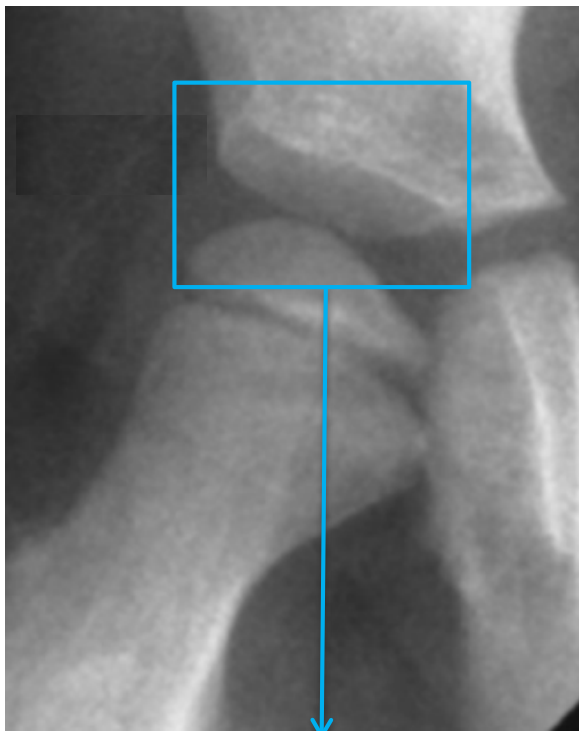
M-line: touches the medial most edge of the femoral head ossific nucleus

P-line: touches the lateral edge of the acetabulum

L-line: touches the lateral most edge of the femoral head ossific nucleus

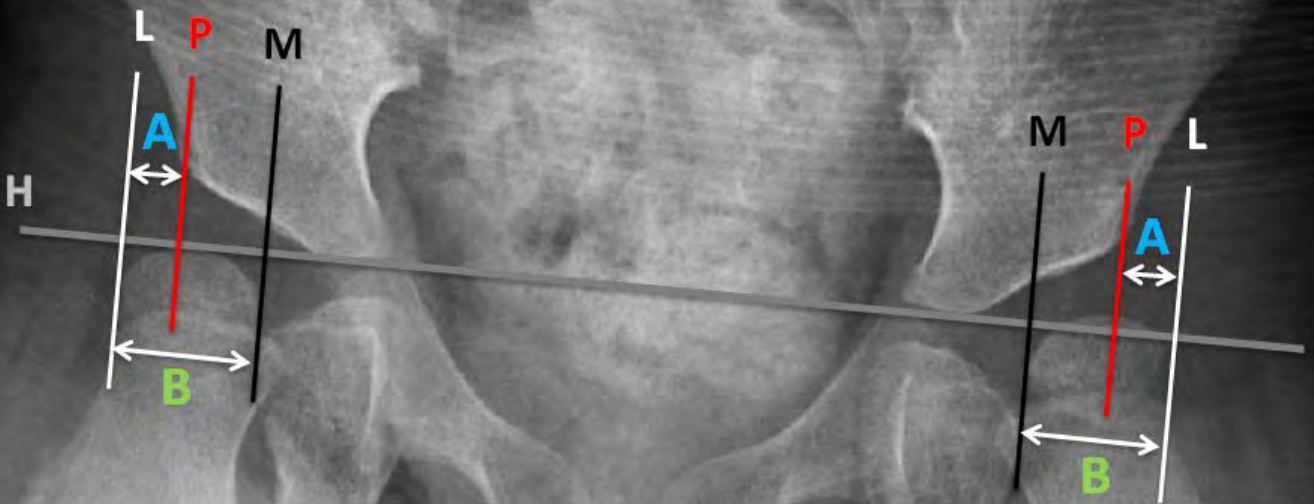


In early cases of hip dysplasia, there may be an upturning of the lateral acetabulum, coined a “Gothic Arch.” In these cases, the **P-Line** should touch the apex of the Gothic Arch (red dot) rather than the lateral edge of the acetabulum (blue dot). This will increase accuracy of the measurement.



STEP 4: Calculate Migration Percentage

$$\text{Migration Percentage} = \frac{A}{B} \times 100\%$$




There is an increased risk of progressive hip displacement if the **Migration Percentage** is equal or greater than

30%



hipscreen.org

Using the Migration Percentage Ruler




HipScreen's **Migration Percentage Ruler** allows you to take a picture of an x-ray and expand the hip to fit a ruler overlay using the device's touchscreen. This allows for a quick calculation of the Migration Percentage without measurement of distance.

Video tutorials showing how to interpret x-rays and how to use the HipScreen app are available under the **Tutorials** tab on www.hipscreen.org.

The image is a screenshot of the HipScreen website's 'Tutorials' page. At the top, there is a navigation bar with links for 'Home', 'How HipScreen Works', 'Why Hip Surveillance?', 'Tutorials' (which is highlighted), 'Resources', and 'More'. To the right of the navigation bar are two buttons: 'Download on the App Store' and 'GET IT ON Google Play'. The main content area features a large image of a hand holding a smartphone displaying the HipScreen app logo. To the right of the smartphone is a blue box with the word 'TUTORIALS' at the top, followed by three buttons: 'Interpreting X-Rays', 'HipScreen Ruler on Apple iOS', and 'HipScreen Ruler on Android'. At the bottom left, there is copyright information for Shriners Hospitals for Children, including the name Vedant Kulkarni, MD, and the address in Sacramento, CA. At the bottom right, it says 'created and designed at' followed by the Shriners Hospitals for Children logo and name.

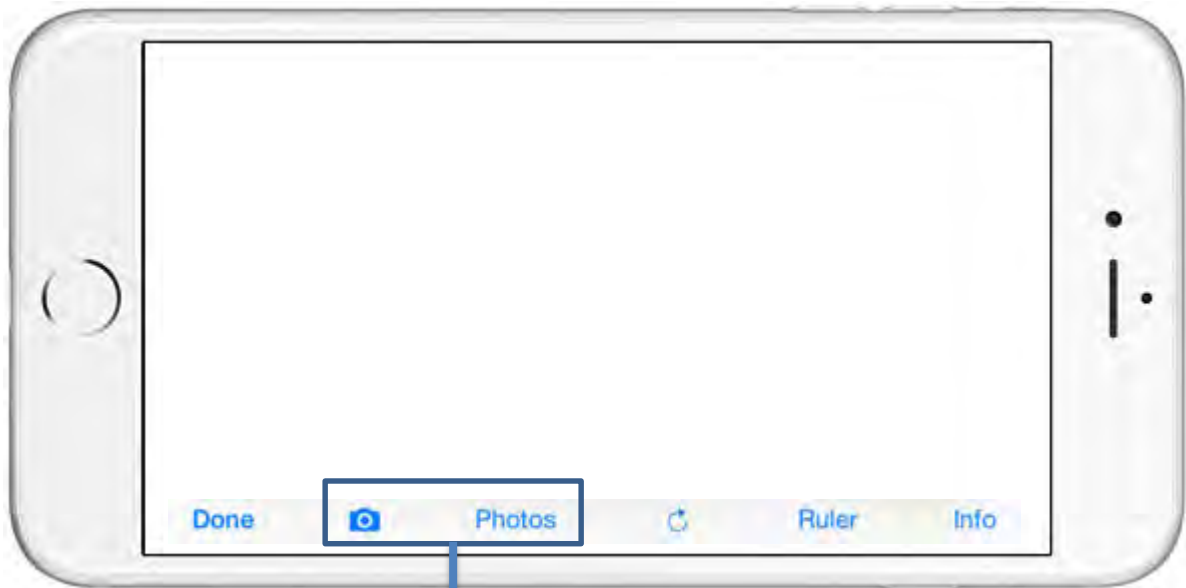© Shriners Hospitals for Children
Vedant Kulkarni, MD
Department of Orthopaedic Surgery
2425 Stockton Blvd
Sacramento, CA 95817

created and designed at
 **Shriners Hospitals**
for Children™

Let's go through the steps to use HipScreen's Migration Percentage Ruler to measure a hip surveillance x-ray.

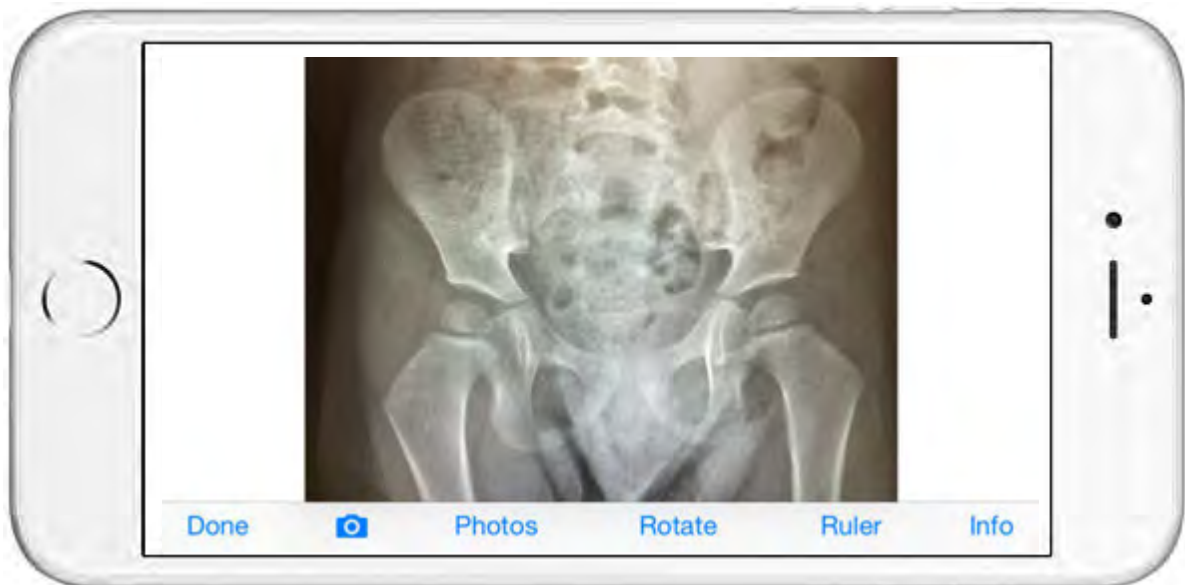
Step 1:

Load the X-Ray image into HipScreen



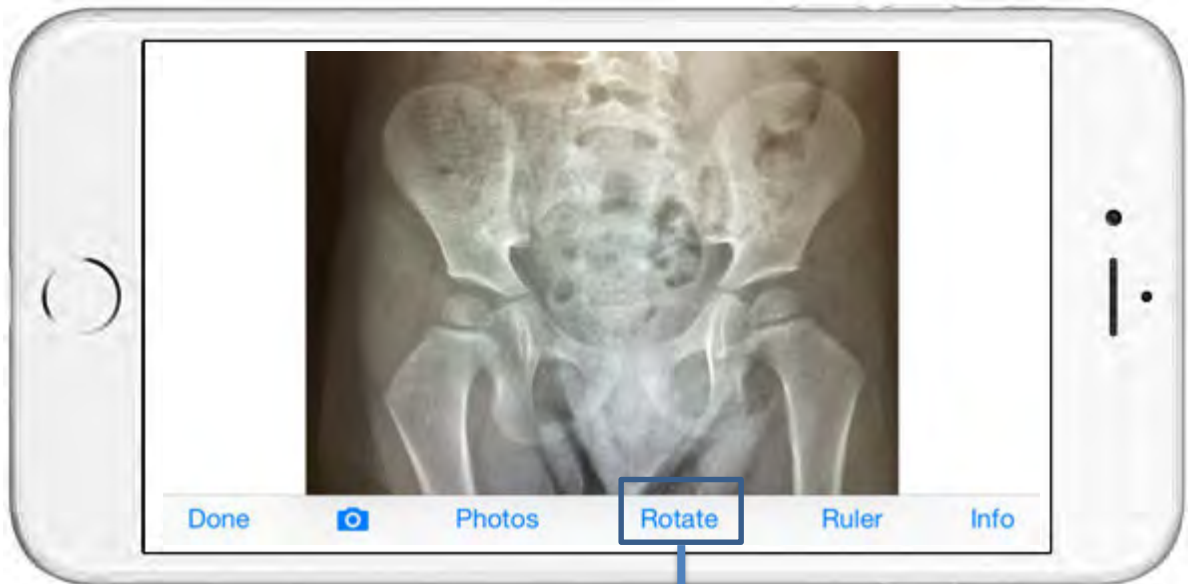Take a picture of an x-ray using the camera icon, or load an x-ray already stored in your “Photos” into HipScreen.

Pictures taken within the HipScreen App are not stored on your phone.



Step 2:

Rotate image to level the pelvis.



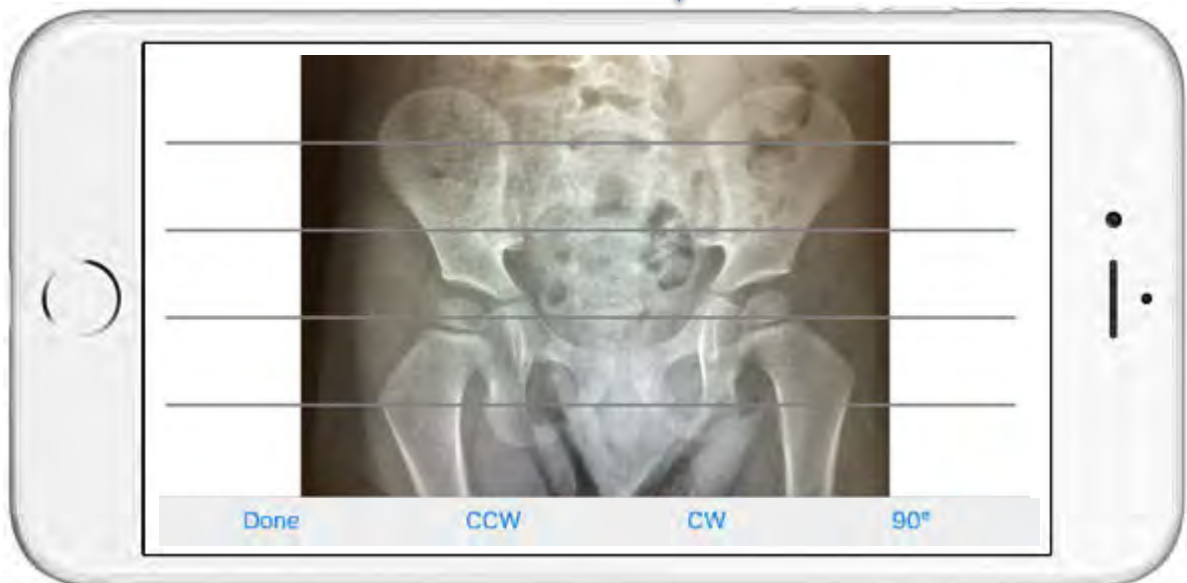
Opens up the Rotate Tool.

“CW” rotates clockwise.

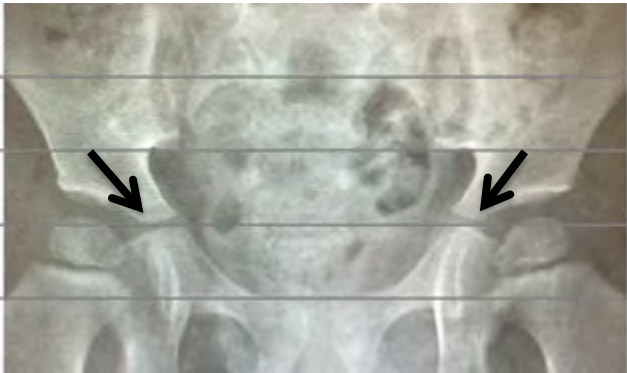
“CCW” rotates counter clockwise.

“90°” turns 90 degrees clockwise.

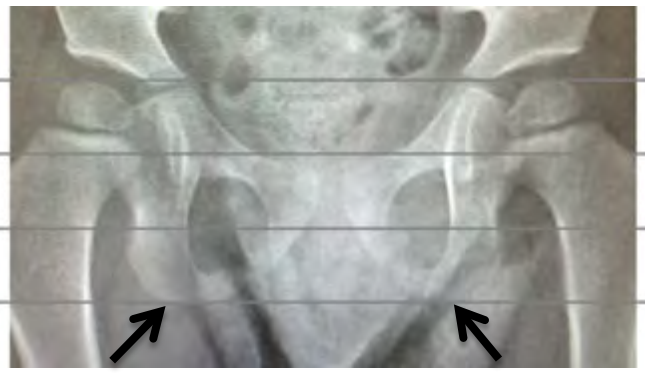
Press “Done” when finished rotating.



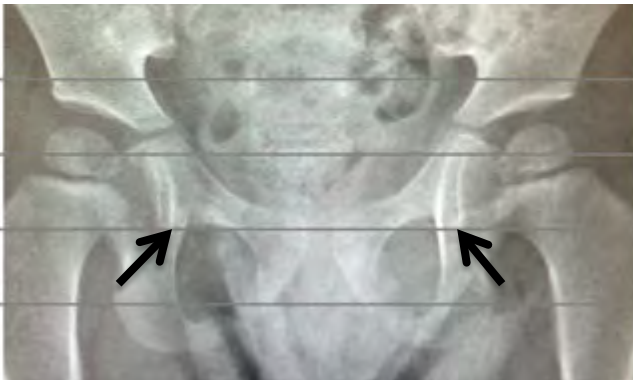
Use the CW and CCW buttons to level the pelvis using any of the common landmarks marked by the arrows below.



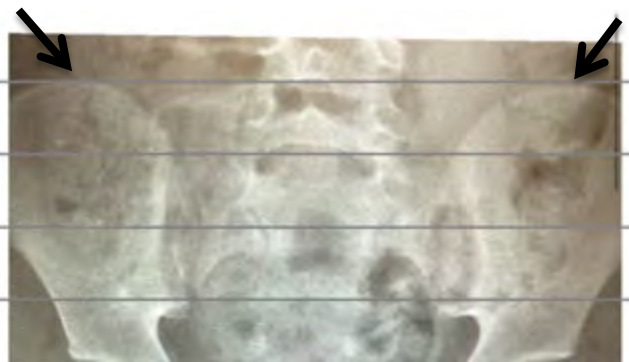
Tri-radiate cartilage



Ischial Tuberosity



Acetabular Teardrop



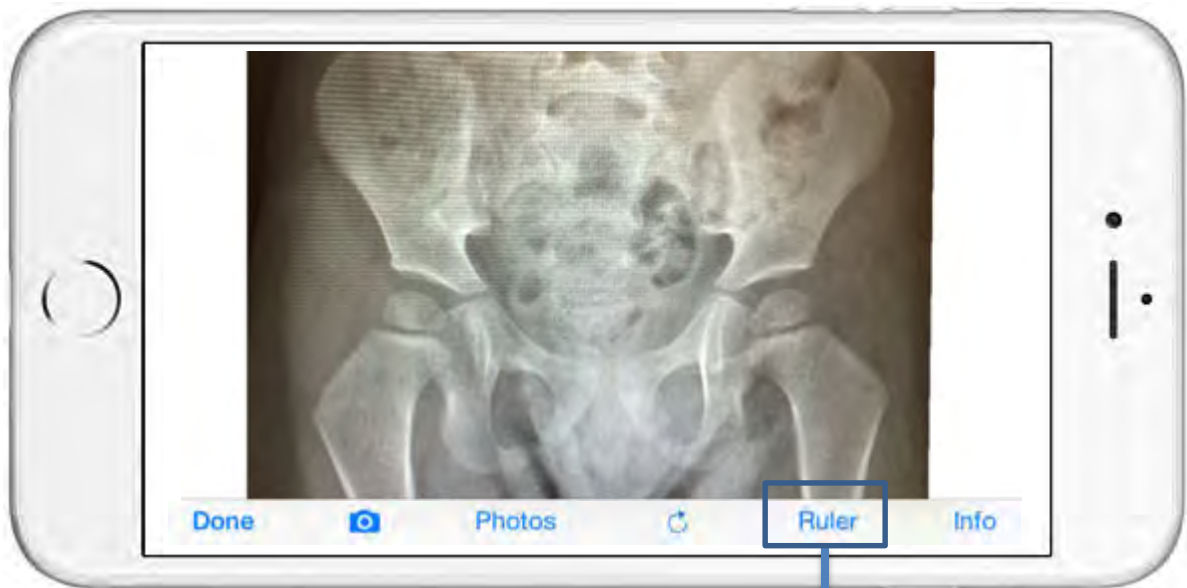Iliac Crest

Remember, you can Pinch-Zoom and Pan to place the lines over the landmarks.



Step 3:

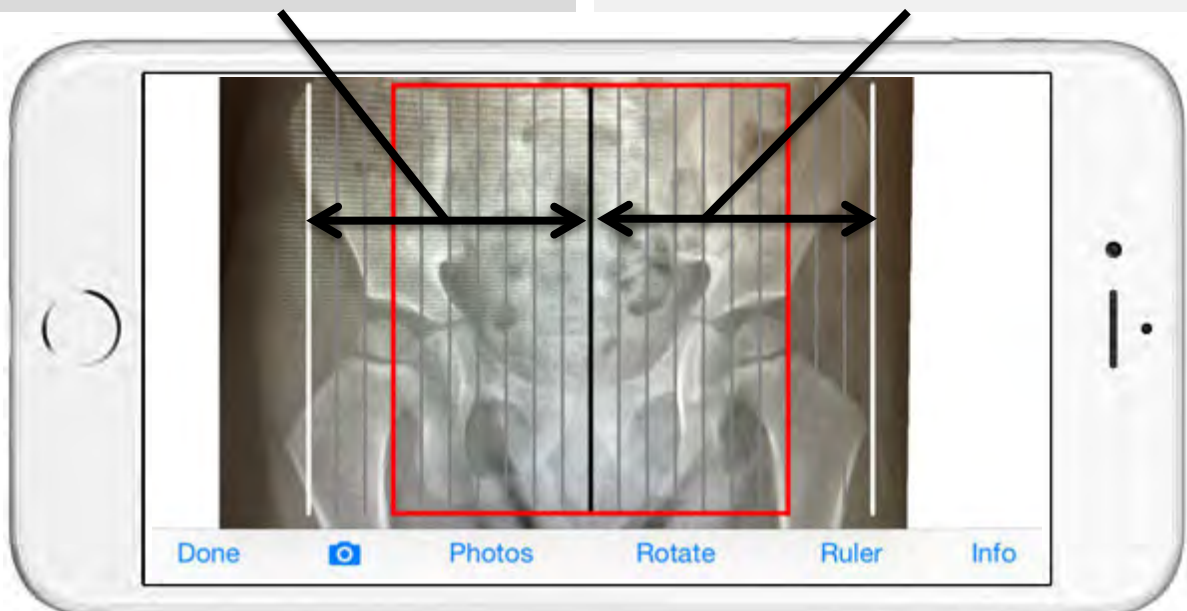
Use the Ruler to determine Migration Percentage.




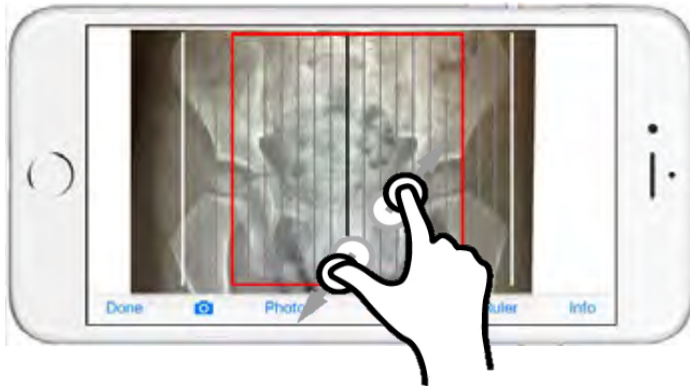
Press “Ruler” to toggle this feature on and off.

The right half of the ruler is used for the hip on the right side of the screen.

The left half of the ruler is used for the hip on the left side of the screen.

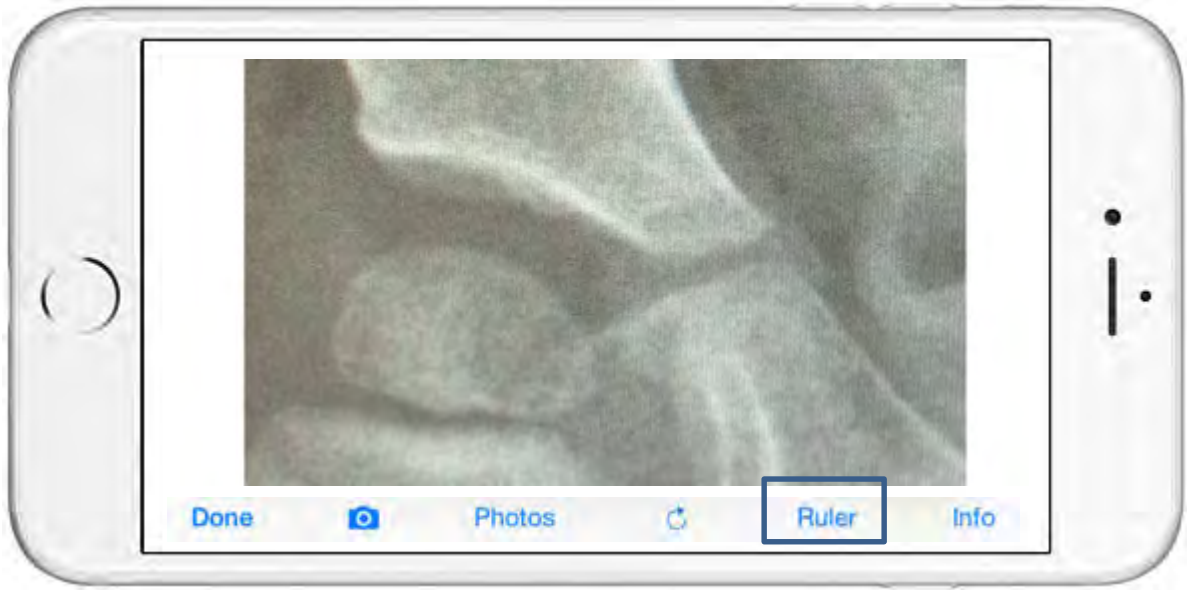

Use the familiar touchscreen features to pinch-zoom and pan the image so that:



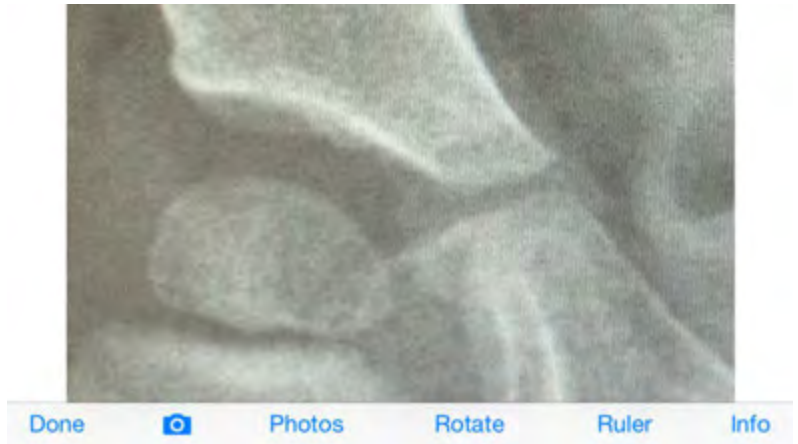
White line touches the lateral border of the femoral head ossific nucleus

Black line touches the **medial** border of the femoral head ossific nucleus




Remember,
you can toggle
the ruler on
and off.

You can also
Pinch-Zoom
and Pan with
or without the
ruler.




Without Ruler Overlay




With Ruler Overlay

When the femoral head ossific nucleus is appropriately positioned between the white and black lines, notice that the vertical lines divide the femoral head into 10% increments.



The lateral edge of the acetabulum touches the 10% line, therefore, 10% of the femoral head is outside the edge of the acetabulum. The Migration Percentage is 10%.

For the hip on the other half of the screen, the other half of the ruler is used to measure the Migration Percentage.

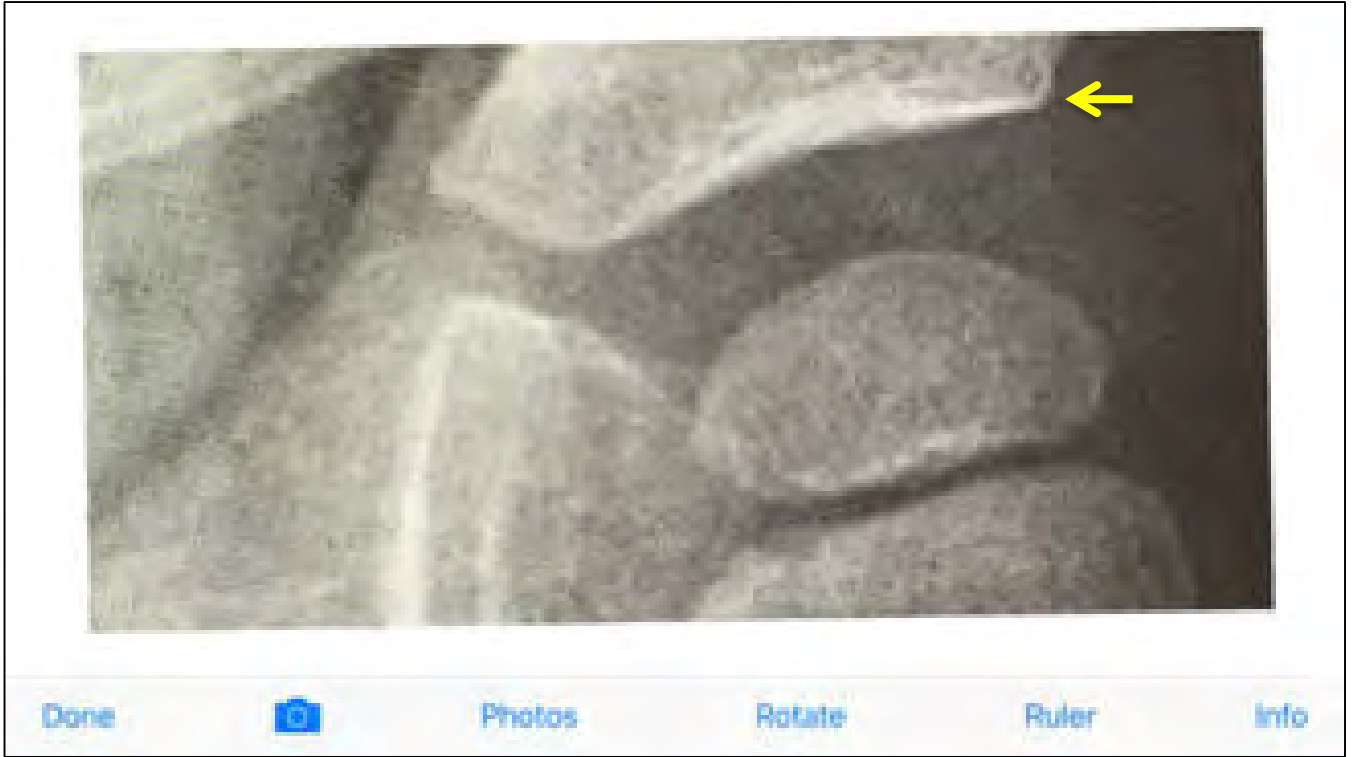


The Migration Percentage is 10% again, because the first gray line touches the lateral edge of the acetabulum.


On the following pages, you will see hips with Migration Percentages of varying degrees.

15% Example

Without Ruler Overlay




With Ruler Overlay




20% Example

Without Ruler Overlay

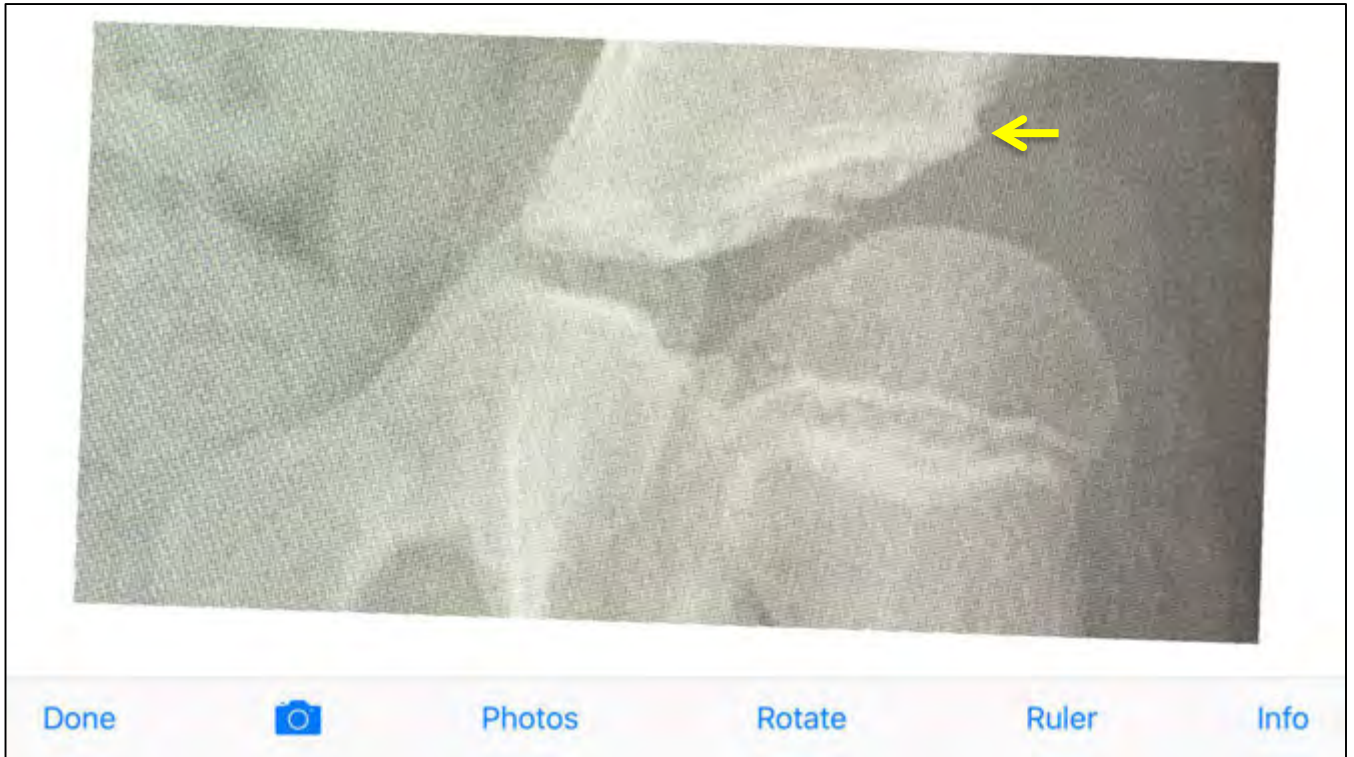

With Ruler Overlay




30% Example

Without Ruler Overlay

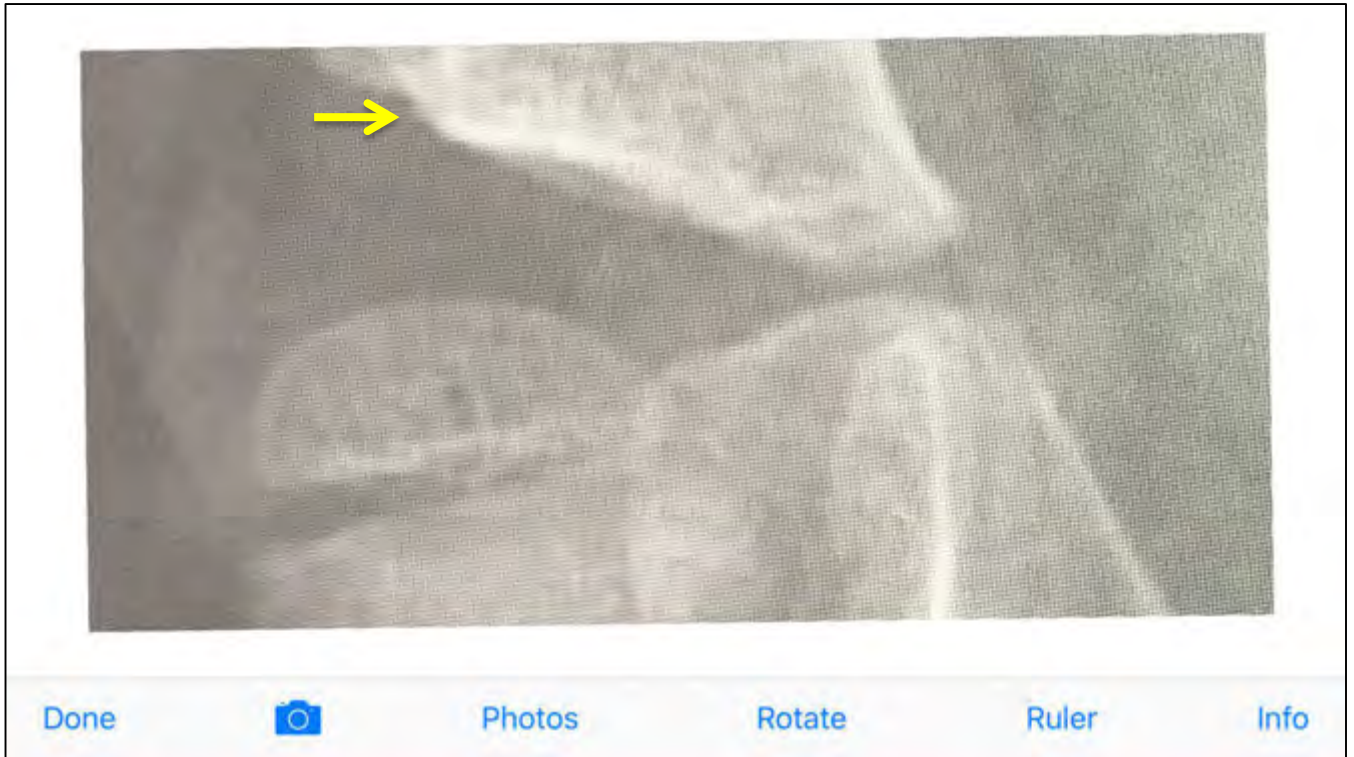

With Ruler Overlay




40% Example

Without Ruler Overlay

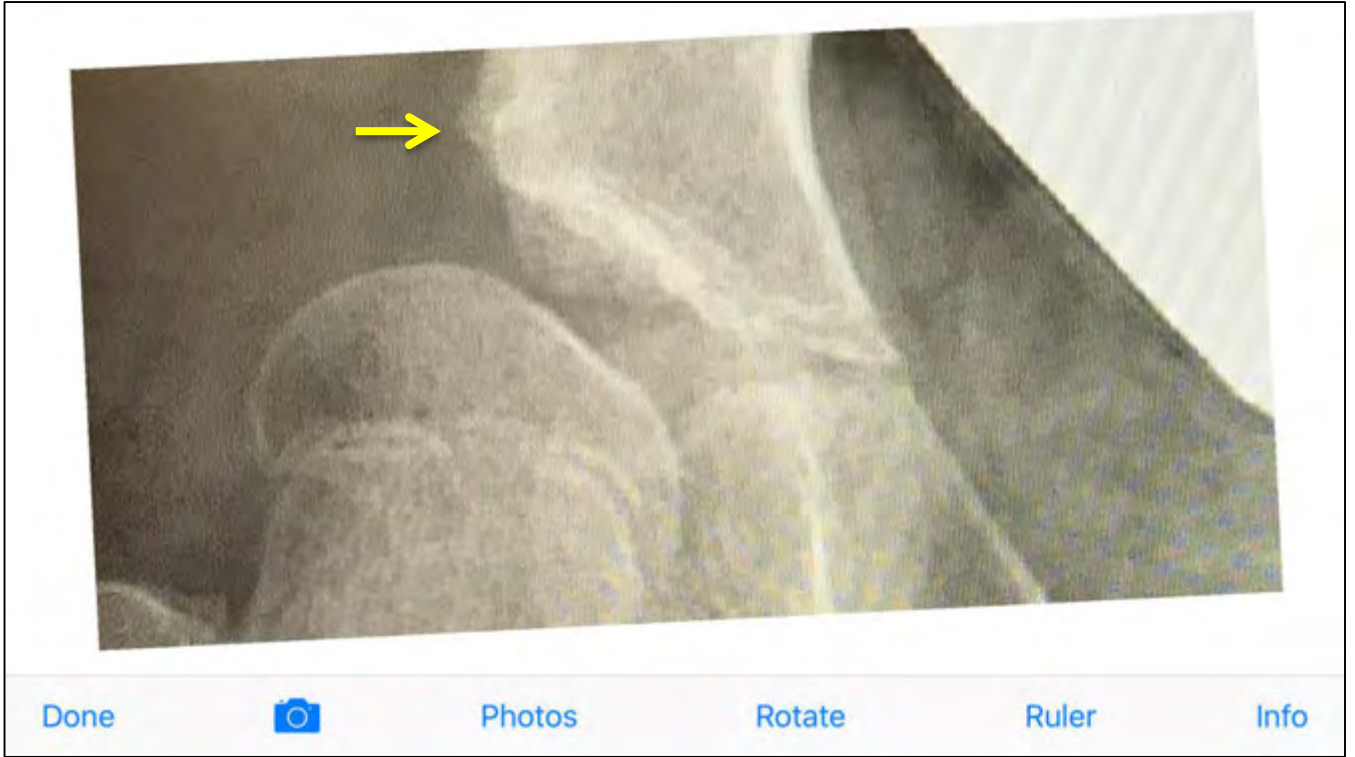


With Ruler Overlay




50% Example

Without Ruler Overlay

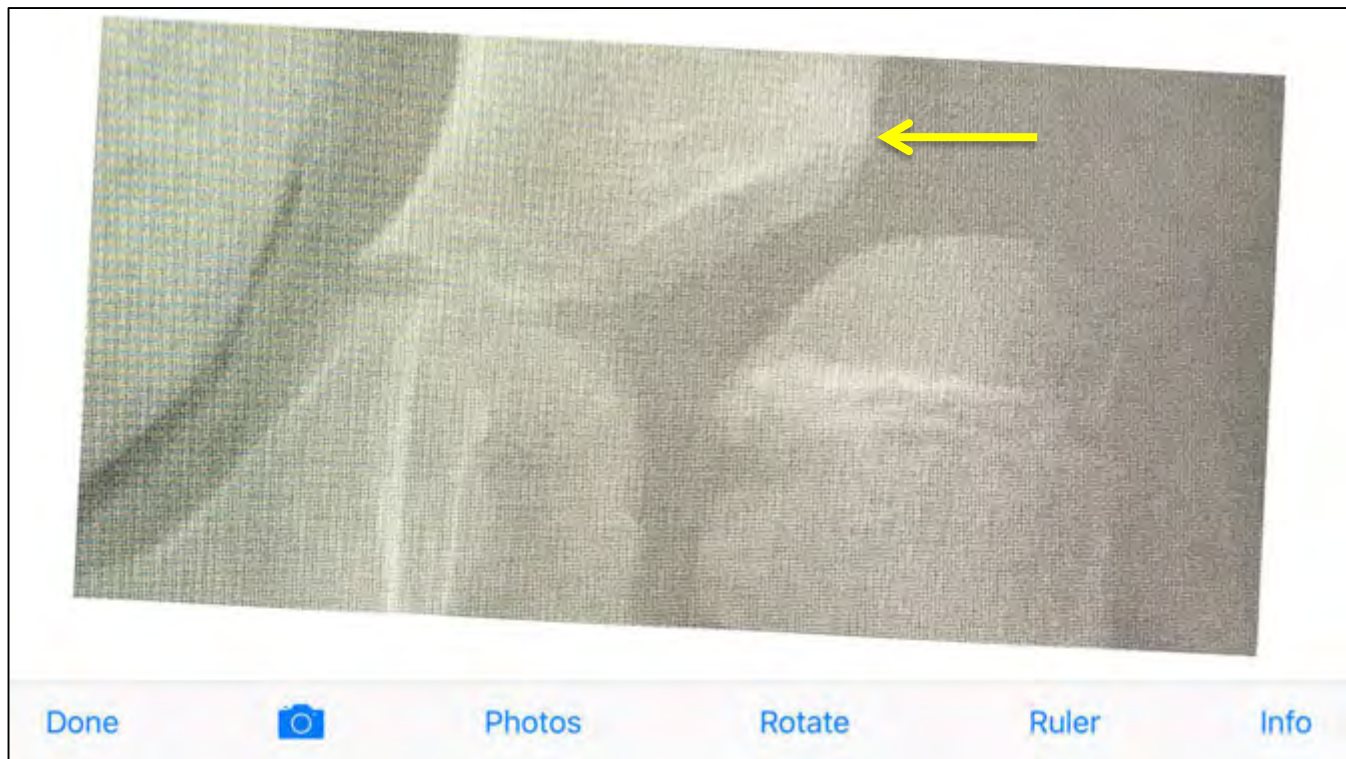


With Ruler Overlay




60% Example

Without Ruler Overlay

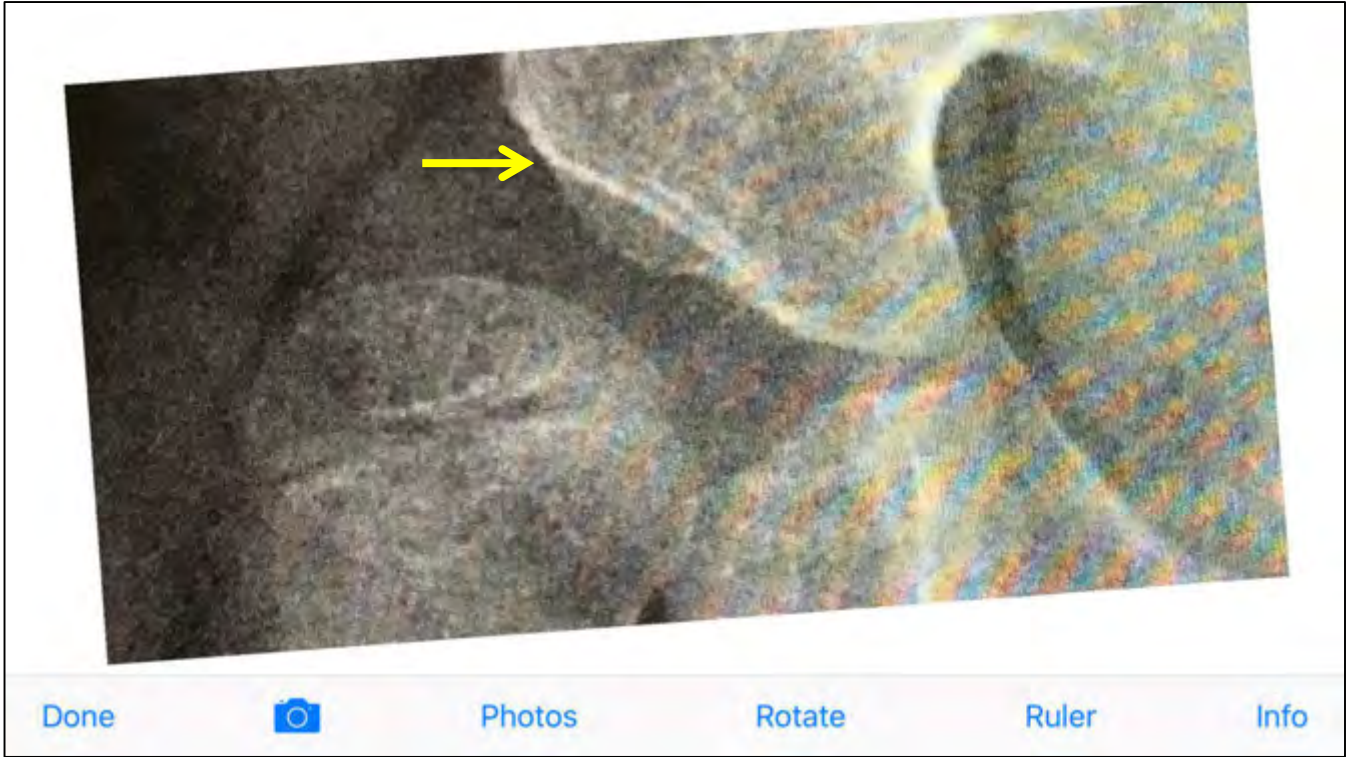


With Ruler Overlay




70% Example

Without Ruler Overlay

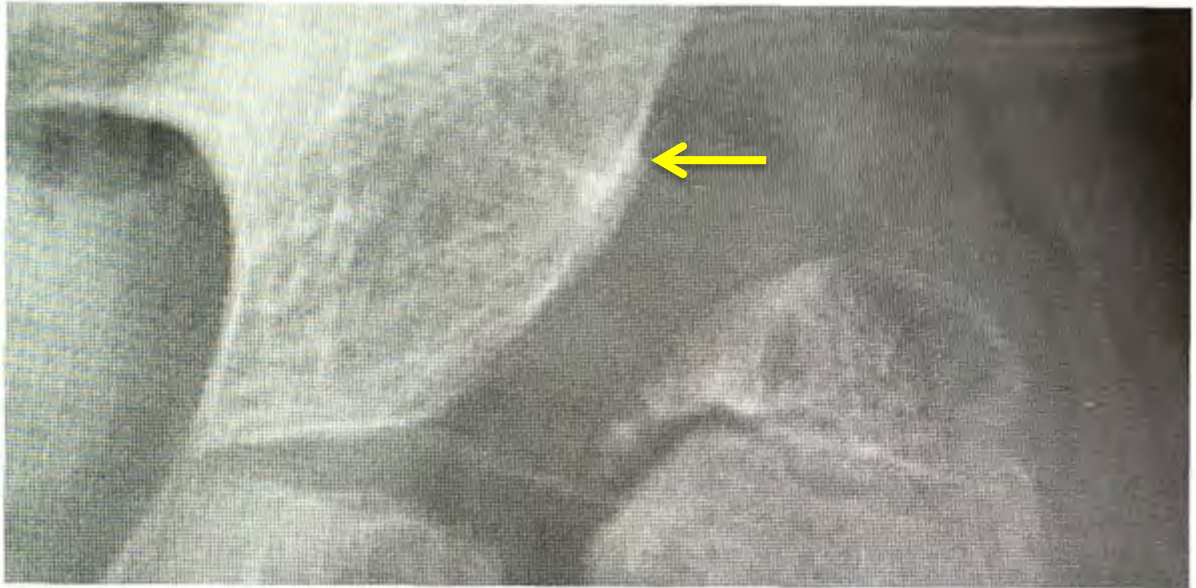


With Ruler Overlay



90% Example

Without Ruler Overlay



Done



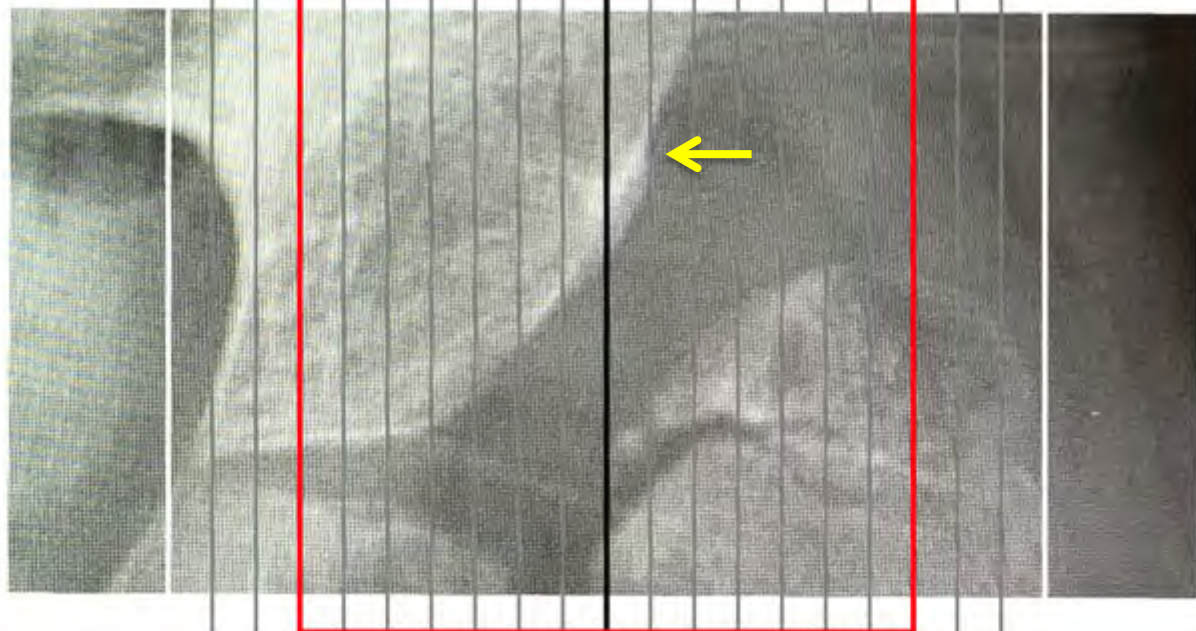
Photos

Rotate

Ruler

Info

With Ruler Overlay



Done



Photos


Rotate

Ruler


Info

Over 100% Example

Without Ruler Overlay




With Ruler Overlay



Remember, 30% is the critical Migration Percentage for a hip at risk of displacement. To make it easier to see, a “red box” contains the high risks zones for both hips.

If the edge of the acetabulum lies within the red box, the Migration Percentage is over 30%.





If the lateral edge of the acetabulum is inside the red box, the migration percentage is above 30%.

Without Ruler Overlay

40%


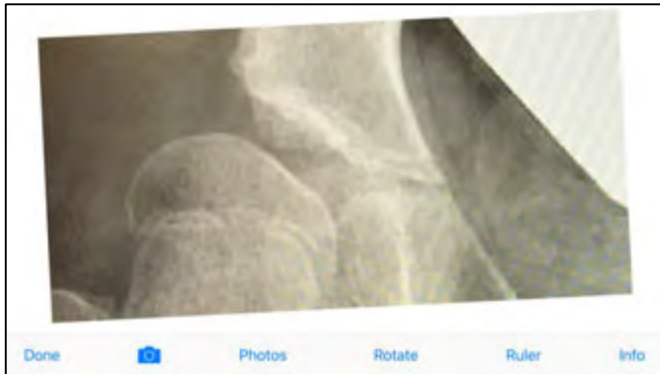
With Ruler Overlay



Without Ruler Overlay

50%

With Ruler Overlay


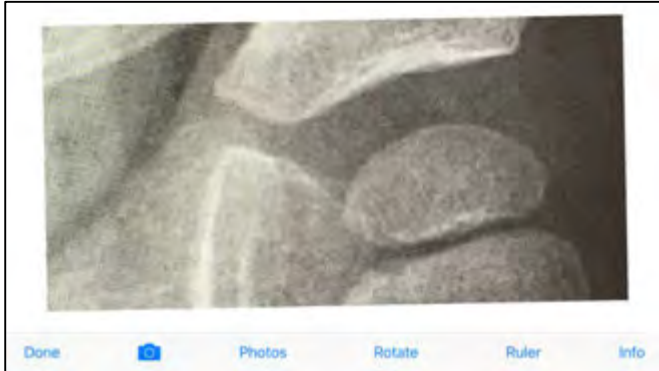


If the lateral edge of the acetabulum is outside the red box, the migration percentage is below 30%.

Without Ruler Overlay

15%


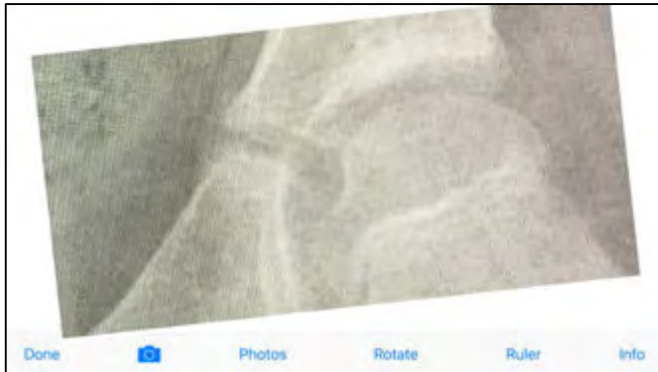
With Ruler Overlay



Without Ruler Overlay

20%

With Ruler Overlay





Clinical Exam for Hip Surveillance

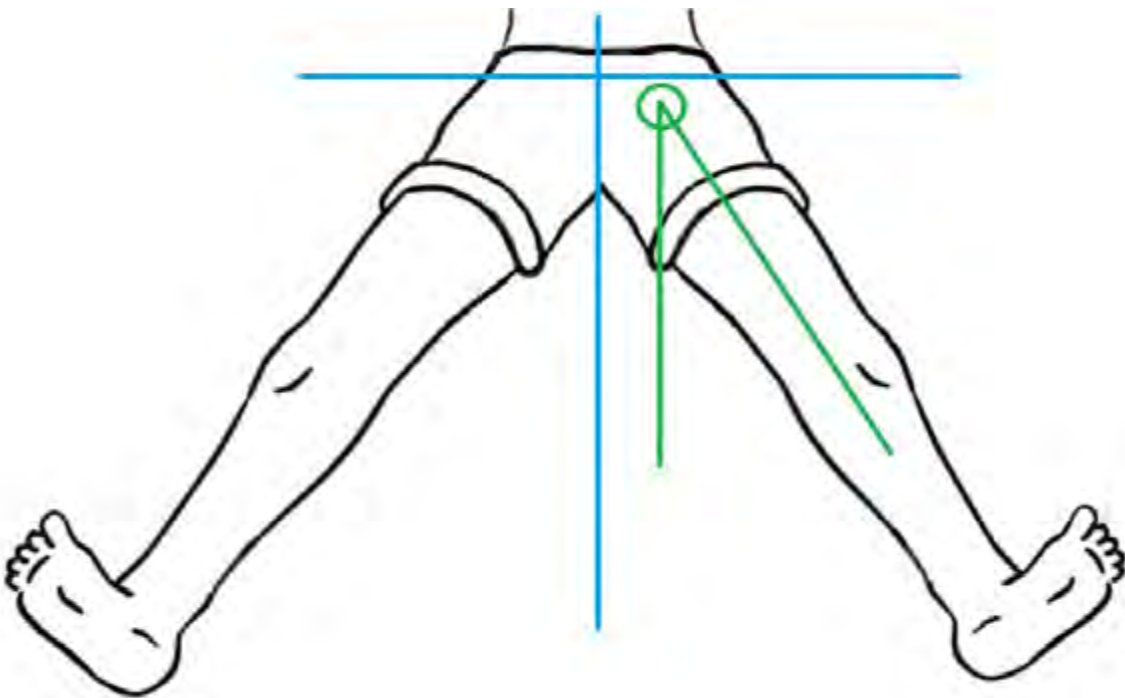
A clinical examination should be performed with each hip surveillance encounter, which includes questions and a clinical assessment.

Important questions to ask the family or caregiver include:

- Does the child have hip pain?
- Is there more difficulty performing personal care, dressing, bathing, or other activities that involve hip motion?
- Has there been a decrease in the child's ability to walk, sit, or stand which might be related to the hip?

Important clinical assessments include:

- Verification of Gross Motor Function Classification System (GMFCS) level. Please see the **Frequently Asked Questions on Hip Surveillance** document for more details on GMFCS Levels.
- Measurement of the maximum hip abduction (green angle) for each hip. Abduction refers to spreading the legs apart.



Maximum hip abduction less than 30 degrees is considered abnormal.



When to Refer to Pediatric Orthopaedics

A referral should be made to a pediatric orthopaedic surgeon if:

- The migration percentage on x-ray is over 30%
- The hip abduction motion is less than 30 degrees
- There is hip pain or decreased function
- There is deterioration in hip motion
- There is asymmetry in hip motion (one side moves less than the other)